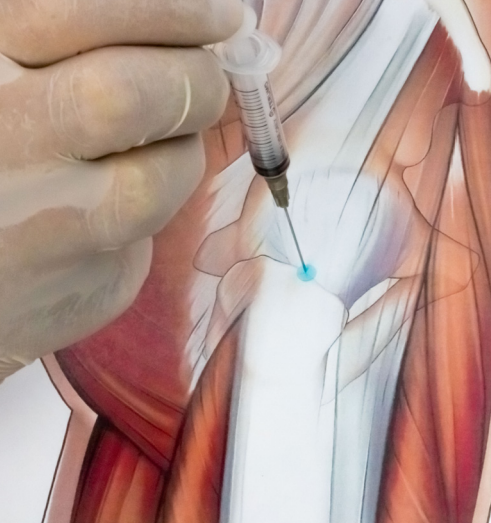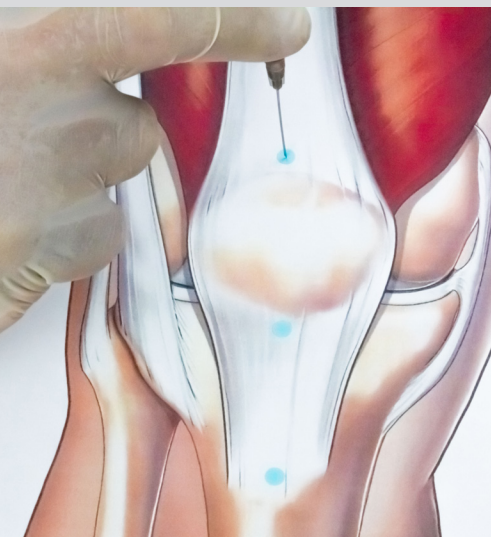
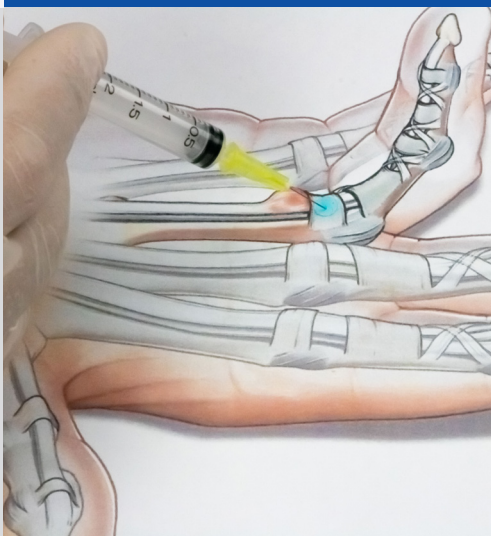


*Scientific Department and  
Medical Direction  
Guna S.p.a.*

*Manual of*  
**INJECTION THERAPY  
FOR THE  
MUSCULOSKELETAL  
SYSTEM**



 **Guna**  
medical device

*COLLAGEN MEDICAL DEVICES*

**ITD** **ITALTRADE  
DISTRIBUTION**



DERMOCOSMETICA

Guna S.p.a.

January 2022

THE INFORMATION CONTAINED HEREIN IS INTENDED FOR USE BY  
PROFESSIONALS ONLY.

Manual of  
INJECTION THERAPY  
FOR THE  
MUSCULOSKELETAL  
SYSTEM

# CONTENTS

9	<b>PRESENTATION</b>
12	<b>BACKGROUND</b>
13	<b>FOREWORD</b>
14	<b>GUNA COLLAGEN MEDICAL DEVICES</b>
14	• CLASSIFICATION
14	• MAIN CHARACTERISTICS
14	- Collagen
15	- Porcine type I collagen
15	• PRODUCT CHARACTERISTICS
16	• MECHANISM OF ACTION
20	• SAFETY AND TOLERABILITY
20	- The immunogenicity and biocompatibility of collagen
20	• FIELDS OF APPLICATION
21	<b>BASICS OF INJECTION TECHNIQUE</b>
21	• GENERAL RULES
21	• MATERIALS
21	- Syringes
22	- Needles
22	- Protocols
23	<b>GUIDE TO MANUAL CONSULTATION</b>



## **25 ANATOMICAL REGIONS DISORDERS INJECTION TECHNIQUES**

### **26 SHOULDER**

#### **26 OSTEOARTICULAR DISORDERS**

- 26 1. Glenohumeral osteoarthritis
- 27 2. Acromioclavicular osteoarthritis
- 27 3. Sternoclavicular osteoarthritis

#### **30 SOFT TISSUE DISORDERS**

- 31 1. Rotator cuff tendinopathy
- 31 2. Tendinopathy of the long head of the biceps brachii
- 32 3. Capsulitis

### **36 ELBOW**

#### **36 SOFT TISSUE DISORDERS**

- 36 1. Epicondylitis
- 36 2. Medial epicondylitis

### **39 HAND/WRIST**

#### **39 OSTEOARTICULAR DISORDERS**

- 39 1. Rhizarthrosis (trapeziometacarpal osteoarthritis)
- 39 2. Metacarpophalangeal osteoarthritis
- 39 3. Proximal interphalangeal osteoarthritis

#### **43 SOFT TISSUE DISORDERS**

- 43 1. De Quervain's tenosynovitis
- 43 2. Trigger finger (stenosing flexor tenosynovitis)
- 43 3. Carpal tunnel syndrome

## **47**

## **HIP**

### **47**

### **OSTEOARTICULAR DISORDERS**

47

1. Hip osteoarthritis

### **49**

### **SOFT TISSUE DISORDERS**

49

1. Greater trochanteric pain syndrome

49

2. Trochanteric bursitis

49

3. Adductor enthesitis

## **53**

## **THIGH**

### **53**

### **SOFT TISSUE DISORDERS**

54

1. Fascia lata disorders

54

2. Quadriceps muscle injury/inflammation

54

3. Flexor muscle injury/inflammation

54

4. Piriformis syndrome

## **58**

## **KNEE**

### **58**

### **OSTEOARTICULAR DISORDERS**

58

1. Femorotibial/ patellofemoral osteoarthritis of the knee

59

2. Patellofemoral chondropathy

59

3. Arthrosynovitis

### **61**

### **SOFT TISSUE DISORDERS**

61

1. Iliotibial band syndrome

61

2. Tendinopathy (quadriceps/ patellar - hamstrings)

61

3. Ligament injury

61

4. Meniscal disorders

**66**      **ANKLE**

**66**      **OSTEOARTICULAR DISORDERS**

- 66      1. Osteoarthritis

**68**      **SOFT TISSUE DISORDERS**

- 68      1. Achilles' tendonitis/tendinosis
- 68      2. Lateral and medial capsuloligamentous injury/  
inflammation

**71**      **FOOT**

**71**      **OSTEOARTICULAR DISORDERS**

- 71      1. Metatarsophalangeal joint pain

**73**      **SOFT TISSUE DISORDERS**

- 74      1. Anterior tibial tendinopathy
- 74      2. Posterior tibial tendinopathy
- 74      3. Peroneal tendinopathy
- 74      4. Plantar fasciitis and calcaneal spurs
- 74      5. Retrocalcaneal bursitis
- 74      6. Morton's neuroma

**79**      **PRODUCTS**

A heartfelt thank you to Dr. Roberto Viganò,  
former Director of the Rheumatic Disease Surgery Unit,  
ASST Gaetano Pini - CTO - Milan, Italy,  
for his valuable scientific contribution  
and the experience lent during the drafting of this manual.

# PRESENTATION

In recent years, the treatment of musculoskeletal disorders has evolved dramatically. Surgical and orthopaedic therapies have progressively dedicated greater attention to Biology and to repair and healing processes, increasingly favouring minimally-invasive techniques and the tissue sparing they afford.

Similarly, non-surgical treatments have followed this trend by focusing increasingly on the Biology of repair processes.

Within this scenario, collagen has become more and more important, and now plays a key role in everyday clinical practice.

Collagen, an element that is present in all the tissues of the musculoskeletal system, has proven to be a valuable ally in the treatment of many acute and chronic inflammatory or degenerative diseases, both with and without pain symptoms.

In Orthopaedics, the great attractiveness of injectable collagen lies in the fact that it can reactivate certain 'dormant' biological processes.

This is its greatest added value, especially (but not solely) in the treatment of chronic diseases, where it clearly proves its capability to induce and accelerate healing processes, precisely where other therapies have failed.

In Surgery - and not only in orthopaedic surgery - collagen is used as a biologically-active scaffold to induce repair responses or to promote new tissue formation processes. It can also be used in non-surgical treatments as a biologically-active scaffold where needed, in order to replace, support, strengthen and protect connective tissues using straight-forward injection techniques.

Guna Collagen Medical Devices are an innovative tool in all healing and repair processes. They are biologically active and also extremely well tolerated.

The special manufacturing process makes collagen completely fluid and therefore easily diffused within the tissues, which allows its use simply through deep or superficial injection techniques.

Moreover, apart from the product's excellent tolerability, the possibility of combining collagen injections with physiotherapy and rehabilitation therapy makes it an outstanding aid for optimising these treatments, as well as pharmacological and surgical treatments, making it an excellent support for repair surgery and a synergistic booster for regenerative therapies.

As orthopaedic specialists, we now have a new therapeutic solution in the form of collagen-based medical devices which may allow us to overcome the partial or complete ineffectiveness of other therapies.

The linear structure and ease of consultation of the Manual of Injection Therapy for the Musculoskeletal System make it a fundamental reference in orthopaedic clinical practice, a daily reference tool, a guide for younger colleagues, and a "good

companion” for all those colleagues who wish to acquire new skills in the field of injection techniques with Guna Collagen Medical Devices.

*Alberto Meroni*

*Specialist in Orthopaedics and Traumatology,*

*Microsurgery and Experimental Surgery.*

*Medical Manager of the Orthopaedics and Trauma Unit,*

*Niguarda Ca' Granda Hospital – Milan, Italy.*

## BACKGROUND

Musculoskeletal disorders (MSDs) are second only to mental and behavioural disorders in terms of their impact on global healthcare. Between 1990 and 2010, this group of disorders (including low back pain, neck pain, osteoarthritis, arthritis, osteoporosis, and other MSDs) was one of the most invalidating in terms of disability-adjusted life years (DALYs) and years lived with disability (YLDs).

Early diagnosis and appropriate treatment would lead to a reduction in disability and to an improvement in prognosis and life expectancy, with a consequent reduction in indirect costs, as the disability and the economic and social costs of managing MSDs are directly proportional to their stage of progression (<https://www.epicentro.iss.it/muscolo-scheletriche/>).



# FOREWORD

The field of musculoskeletal disorders involves an extremely diverse range of pharmacological, physical rehabilitation and surgical interventions.

Over the past decade, there has been increasing interest and success of conservative treatments for musculoskeletal diseases, including those interventions aimed at repairing and regenerating musculoskeletal tissues, which are jointly referred to as Functional Tissue Engineering (FTE).

More recently, in the field of Functional Tissue Engineering, a new approach to painful musculoskeletal disorders is represented by bio-scaffolds of the extracellular matrix, containing porcine type I collagen and ancillary substances, to be administered by local injections.

The aim is twofold: on the one hand, the induction of repair and regeneration processes. On the other hand, and this is one of the most interesting aspects, a reduction of the time required for the functional recovery of the injured tissue, a matter of crucial importance in Orthopaedics, Sports Medicine, Physical and Rehabilitation Medicine.

GUNA COLLAGEN MEDICAL DEVICES represent a new approach in the field of Functional Tissue Engineering, with intra- articular and extra-articular injections of porcine collagen.

# GUNA COLLAGEN MEDICAL DEVICES

## CLASSIFICATION

Guna Collagen Medical Devices are class III medical devices containing injectable collagen. They are classified and placed on the market in accordance with Directive 93/42/EEC of 1993.

## MAIN CHARACTERISTICS

### Collagen

Collagen accounts for 5-6% of adult body weight and is the most abundant protein in Mammals. Collagen is the fundamental constituent of ligaments, tendons, capsules, bones, cartilage, muscles, skin and, in general, of the extracellular matrix (ECM) (Boot-Handford and Tuckwell, 2003).

The smallest subunit of collagen is tropocollagen, which consists of sequences of glucose/galactose units and 4 amino acids (Proline, Hydroxyproline, Glycine and Lysine).

To date, 28 types of collagen have been identified (21 in Mammals), consisting of 46 separate polypeptide chains combined in different ways to give each type the required tissue-specific characteristics. All types of collagen have a characteristic triple-helix structure: the length of the helix and the width and the nature of the non-helical portion vary depending on the type of collagen (Silvipriya et al., 2015). Type I collagen is the most common. It can be isolated from skin, bone, teeth, tendon, and it is suitable for medical applications (Todhunter et al., 1994; Silvipriya et al., 2015).

Collagen is obtained by extraction and hydrolysis from various animal sources. Common sources of collagen for tissue engineering applications include bovine skin and tendons, porcine dermis, and equine tendons and dermis.

## Porcine type I collagen

The collagen used in Guna Collagen Medical Devices is type I collagen of porcine origin, which is preferred to bovine collagen because it is structurally more similar to human collagen.

At genetic level, the similarities between the two mammalian species *Sus scrofa domesticus* and *Homo sapiens* are remarkable. In fact, they have similar genome composition and size, and both genes and sequences are highly preserved in the two species.

Nucleotide sequences, gene location, length and number of coding regions, and non-coding DNA content are just some of the genetic aspects that pigs and humans have in common.

Using porcine collagen guarantees high levels of safety on account of its very low immunogenicity: this makes it a material of choice also for numerous applications in aesthetic medicine, from the production of bio-scaffolds to dermal fillers (Catena et al., 2007; Narins et al., 2007; Solish, 2010; Sage et al., 2011; Brandão et al., 2013).

The glycoprotein sequences of chains  $\alpha 1$  and  $\alpha 2$  of human and porcine type I collagen show 97% and 94% homology, respectively.

## PRODUCT CHARACTERISTICS

Each vial of Guna Collagen Medical Device (2 ml) contains 100  $\mu$ g of collagen.

In addition to collagen, each type of Guna Collagen Medical Devices contains different selected ancillary substances of vegetable, mineral or vitamin origin that support the mechanical action of collagen, with supporting activity.

This volume is focused on 7 different Collagen Medical Devices, which can be classified as **“articular”**

- MD-KNEE
- MD-SHOULDER
- MD-HIP
- MD-SMALL JOINTS

and as **“non-articular”**

- MD-TISSUE
- MD-MUSCLE
- MD-NEURAL

## MECHANISM OF ACTION

Due to the presence of hydrolysed type I collagen, Guna Collagen Medical Devices act as a bio-scaffold of the extracellular matrix. Following their locoregional injection, they act through the deposition of collagen fibrils in the damaged region (Milani, 2010). The collagen present in Guna Collagen Medical Devices is injected locally in order to replace, strengthen, structure and protect the tissues of the musculoskeletal system: it improves the anatomical and functional structure of the collagen fibres, of the structures containing them, and it provides mechanical support to the treated areas.

Guna Collagen Medical Devices have a mechanical action, due to an induced increase in the anisotropy (i.e. tensile forces) of the extra-cellular matrix (anisotropy depends on the integrity and the proper alignment of the collagen fibres). The local collagen supplementation improves anisotropy and increases tensile forces. It is known that the sub-fibrils constituting collagen fibrils express a certain degree of anisotropy when they are mechanically stressed (Wenger et al., 2007).

Restoring the anisotropy of collagen fibres through the local injection of Guna Collagen Medical Devices induces the same biological response that is achieved with eccentric exercise, typical of the phases of functional recovery from tendon injury. The signal induced by stimulating integrins causes the cascade of growth factors (TGF-beta 1, CTGF, IGF-1) required for the production of new collagen by the fibroblast [Silbernagel, 2011].

In an in vitro research study, tenocytes grown on a coating of type I collagen (namely MD-Tissue) showed a significant increase in tenocyte proliferation, and the synthesis and increased migration of type I collagen (Randelli et al., 2018).

The study suggests that the local injection of collagen is able to mechanically reactivate the fibroblast's ability to synthesise new collagen, thereby inducing autologous repair and remodelling mechanisms in the damaged connective tissue. In addition, fibroblasts are able to generate tensile forces as well as receive them. These fibroblast contraction forces are essential for wound healing processes.

The main *rationale* of the **“articular” Guna Collagen Medical Devices** (MD-KNEE, MD-SHOULDER, MD-HIP, MD-SMALL JOINTS) is their action on chondrocytes.

The increase in tensile forces, generated by the injection of type I collagen, influences chondrocyte metabolism and is crucial for the structural integrity and functional efficiency of the cartilage (Millward-Sadler et al., 2004).

The integrins, present on the chondrocytes cell surface, convert the increased tensile forces into a biological response (integrin mechanotransduction effect) [Oesser et al., 2003; Siebert et al., 2010].

The neo-synthesis of type II collagen is one of the most crucial biological responses secondary to the effects of mechanotransduction. The neo-synthesis of type II collagen in the cartilage contributes to the structural recovery of the cartilage itself and, consequently, to the functional recovery of the joint.

The main clinical outcome of Guna Collagen Medical Devices is the improvement in the joint's functional recovery by slowing the degenerative processes and promoting the repair processes of the joint.

This is supported by the clinical study *A double-blind, randomised, active-controlled clinical trial on the intra-articular use of MD-KNEE vs. sodium hyaluronate in patients with knee osteoarthritis ("Joint Study")* published in 2016, which demonstrated the positive effects of MD-Knee on knee joint pain and function in patients with Kellgren-Lawrence grade II-III knee osteoarthritis (Martin Martin et al., 2016).

The main rationale of the mechanical action of the **“non-articular” Guna Collagen Medical Devices** (MD-TISSUE, MD-MUSCLE, MD-NEURAL), is their action on fibroblasts.

The main clinical outcome of Guna Collagen Medical Devices is the improvement in the functional recovery of soft tissues by slowing degenerative processes and improving the repair processes of the soft tissues.

The preclinical study *Effect of a Collagen-Based Compound on Morpho-Functional Properties of Cultured Human Tenocytes*, published in 2018, demonstrated the positive effects of MD-Tissue on the synthesis of type I collagen and on the modulation of its synthesis and degradation caused by MMPs (Metalloproteinases) and TIMPs (Tissue Inhibitors of Metalloproteinases). Another aspect of clinical interest is the centripetal migration of tenocytes (belonging to the fibroblast family) to the wound area, which results in a reduction in wound width (Randelli et al., 2018).

Subsequently, the pre-clinical study *The Collagen-Based Medical Device MD-Tissue Acts as a Mechanical Scaffold Influencing Morpho-Functional Properties of Cultured Human Tenocytes* was published in 2020, highlighting the evident mechanical action of collagen medical devices (Randelli et al., 2020).

The paper *Treatment of lateral epicondylitis with collagen injection: a pilot study*, published in 2019, demonstrated the positive effects of MD-Tissue on the functional recovery of the elbow joint (Corrado et al., 2019).

Two clinical studies were published in 2020. The first one, *Ultrasound-guided collagen injections for treatment of plantar fasciopathy in runners: A pilot study and case series*, showed the positive effects of MD-Tissue in the treatment of plantar fasciitis (Corrado et al., 2020 a). The second one, *Use of injectable collagen in partial- thickness tears of the supraspinatus tendon: a case report*, reported the positive effects of MD-Tissue in the treatment of supraspinatus muscle tendon injuries (Corrado et al., 2020 b).

The clinical study *Comparison between Collagen and Lidocaine Intramuscular Injections in Terms of Their Efficiency in Decreasing Myofascial Pain within Masseter Muscles: A Randomized, Single-Blind Controlled Trial*, published in 2018, suggests the greater effects of MD-Muscle compared to Lidocaine 2% in controlling pain and muscle contracture in myofascial pain dysfunction syndrome in the masseter muscles (Nitecka-Buchta et al., 2018).

Another particularly interesting clinical study, *Combination of in-situ collagen injection and rehabilitative treatment in long-lasting facial nerve palsy: a pilot, randomized, controlled trial*, published in 2020, demonstrated the positive effects of using a mix of different collagen medical devices (MD-Muscle + MD-Neural + MD-Matrix) in the treatment of long-lasting facial nerve paralysis (Micarelli et al., 2020).

## **SAFETY AND TOLERABILITY**

### **The immunogenicity and biocompatibility of collagen**

Scientific literature supports the biomedical applications of type I collagen, based on the low immunogenicity and good biocompatibility of collagens, the origin and interspecies homology of the collagen (especially between human and porcine collagen), the therapeutic applications of collagen and the safety of porcine type I collagen.

Type I collagen is suitable for implantation due to its high bioavailability and low immunogenicity. The great biocompatibility and inherent biodegradability of endogenous collagenases make exogenous collagen ideal for use in biomedical applications (Chattopadhyay and Raines, 2014; Tang and Saito, 2015; Deshmukh et al., 2016). An analysis of immunological data on the clinical use of collagens showed no evidence of adverse immunological responses induced by the collagens, regardless of their origin and the extraction methods used to obtain them (Lynn et al., 2004; Tang and Saito, 2015; Deshmukh et al., 2016).

## **FIELDS OF APPLICATION**

From a clinical point of view, Guna collagen medical devices can be considered as extracellular matrix bio-scaffolds able to support the repair and regeneration mechanisms. Connective tissues can be deteriorated due to overuse, ageing or injuries causing pain symptoms in the musculoskeletal system.



# BASICS OF INJECTION TECHNIQUE

## GENERAL RULES

- Obtain patient's informed consent.
- Replace the needle used to draw the product from the vial with the specific needle for the injection to be performed.
- Identify landmarks, to be marked using a dermatographic pen if necessary.
- Disinfect the skin thoroughly with iodopovidone or chlorhexidine, starting from the entry point to be used, progressively enlarging the disinfected with eccentric movements.
- Use sterile gloves.
- Apply a medicated patch onto the injection site.

## MATERIALS

### SYRINGES



- 2.5 ml



- 5 ml



- 10 ml

## NEEDLES



- 26G x 13 mm



- 22G x 32 mm



- Spinal needle  
20G x 90 mm

## PROTOCOLS

- When required by the specific clinical situation, different Collagen Medical Devices can be mixed in the same syringe.
- Treatment scheme: 1 injection per week to reduce the physiological deterioration of the joints and tissues (tendons and ligaments). Results are evident after 3 or 5 injections.
- In acute cases, the injections can be carried out twice a week.

# GUIDE TO MANUAL CONSULTATION

This manual is structured and organised according to **Anatomical Regions**.

For each anatomical region the following are indicated:

- Joint disorders
- Soft tissue disorders

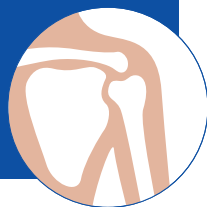For each disorder, the following are specified:

- The Medical Device to be used
- The recommended position of the patient
- The injection technique
- The anatomical landmarks and approaches
- The recommended needles
- Images illustrating the recommended techniques, anatomical landmarks, approaches.



ANATOMICAL REGIONS  
DISORDERS  
INJECTION TECHNIQUES

# SHOULDER



## OSTEOARTICULAR DISORDERS

Disorders secondary to ageing, postural defects and overload, trauma, and injury, such as:

1. GLENOHUMERAL OSTEOARTHRITIS
2. ACROMIOCLAVICULAR OSTEOARTHRITIS
3. STERNOCLAVICULAR OSTEOARTHRITIS

### MD

1. MD-SHOULDER
2. MD-SHOULDER
3. MD-SHOULDER

### PATIENT POSITION

1. Sitting, arms folded
2. Sitting
3. Sitting or supine

### LANDMARKS/ APPROACHES

1. GLENOHUMERAL OSTEOARTHRITIS

Insert the needle below the inferior margin of the posterior angle of the acromion, in the direction of the coracoid process, until contact with the humeral cartilage is felt (Fig. 1, page 28).

## 2. ACROMIOCLAVICULAR OSTEOARTHRITIS

Insert the needle into the upper part of the acromioclavicular joint line, perpendicular to the skin plane (Fig. 2, page 29).

## 3. STERNOCLAVICULAR OSTEOARTHRITIS

Insert the needle into the anterior portion of the sternal-clavicular joint line, perpendicular to the skin (Fig. 3, page 29).

## TECHNIQUE

1. Intra-articular
2. Intra-articular or peri-articular
3. Intra-articular or peri-articular

## NEEDLES

1. 22G x 32 mm
2. 26G x 13 mm
3. 26G x 13 mm

## Literature on Guna Collagen Medical Devices in the disorders of the **SHOULDER** anatomical region

- Corrado B., Bonini I., Alessio Chirico V., Rosano N., Gisonni P.  
– Use of injectable collagen in partial-thickness tears of the supraspinatus tendon: a case report. *Oxf Med Case Reports*. 2020;2020(11):omaa103.
- Nestorova R. et al. – Clinical and sonographic assessment of the effectiveness of Guna Collagen MDs injections in patients with partial thickness tear of the rotator cuff. *Physiological Regulating Medicine*, 2016-2017; 35-37.

- Nestorova R., Rashkov R., Reshkova V. – Clinical and sonographic assessment of the effectiveness of collagen injections Guna MDs in shoulder periarthrititis with bursitis. European Journal of Musculoskeletal Diseases, Vol.3, no. 1, January-June (2014).
- Ottaviani M. – Treatment of joint conditions with Guna Collagen Medical Devices – clinical study on 257 patients. Physiological Regulating Medicine 2018; 18-25.
- Zurita Uroz N. – Collagen Medical Device infiltration in shoulder pathologies. Calcific supraspinatus tendinitis. Physiological Regulating Medicine 2017; 15-17.

## LANDMARKS AND APPROACHES - FIGURES

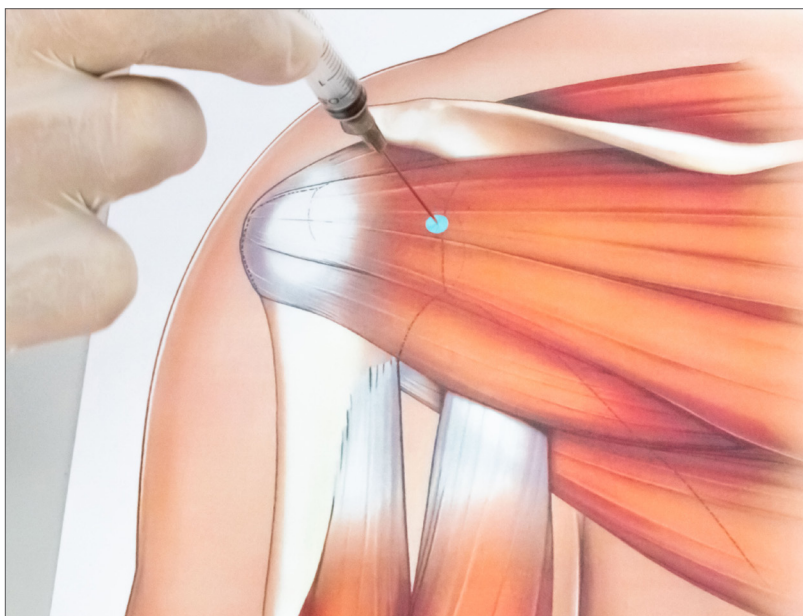


Fig. 1: Glenohumeral osteoarthritis.



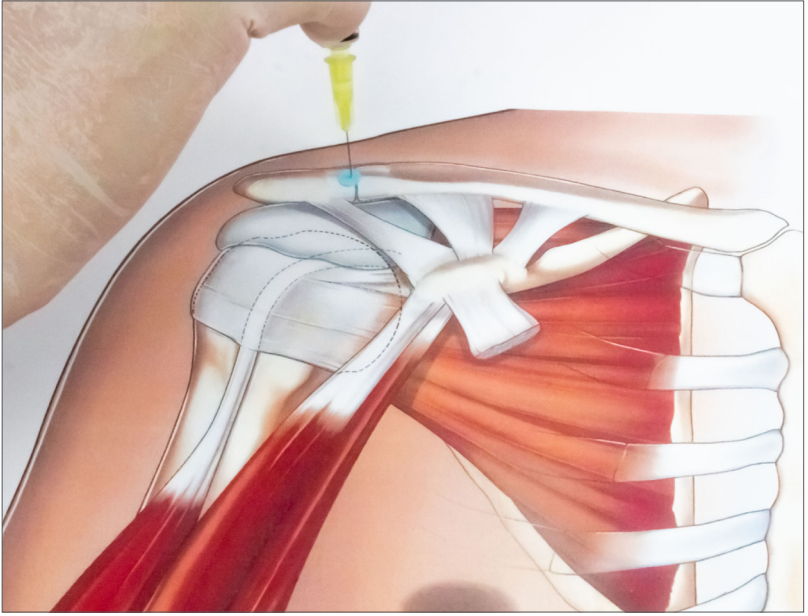


Fig. 2: Acromioclavicular osteoarthritis.

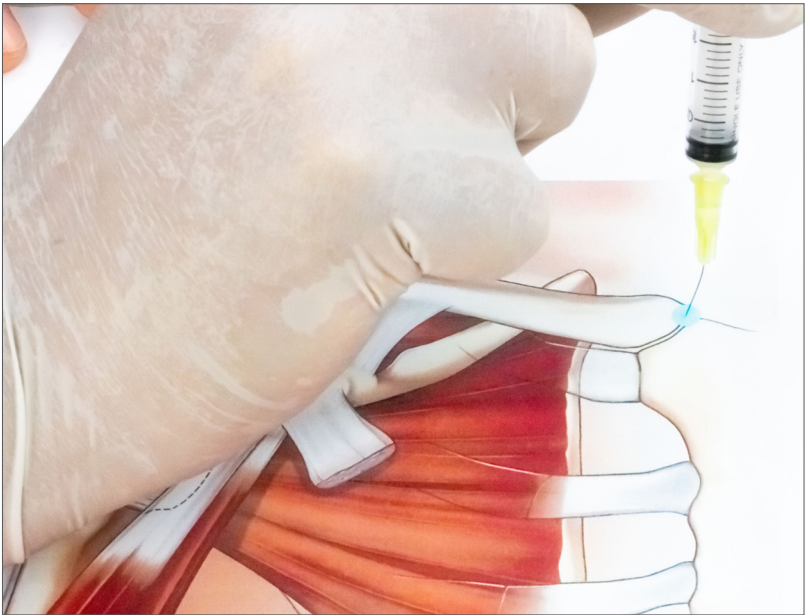


Fig. 3: Sternoclavicular osteoarthritis.

# SOFT TISSUE DISORDERS

Disorders secondary to ageing, postural defects and overload, trauma, and injury, such as:

1. ROTATOR CUFF TENDINOPATHY
2. TENDINOPATHY OF THE LONG HEAD OF THE BICEPS BRACHII
3. CAPSULITIS

## MD

1. MD-TISSUE
2. MD-TISSUE
3. MD-TISSUE (in combination with MD-NEURAL in case of persistent pain)

## PATIENT POSITION

1. Sitting
2. Sitting or supine
3. Sitting

## LANDMARKS/ APPROACHES

### 1. ROTATOR CUFF TENDINOPATHY

**Anterior approach** (Fig. 4, page 33).

*Landmarks*

- Lower margin of the acromion and the acromioclavicular joint; insert the needle perpendicular to the skin about 1 cm below this margin, then tilt the needle slightly upwards and laterally.

**Lateral approach** (Fig. 5, page 33).

*Landmarks*

- Acromiohumeral interval, at the beginning of the anterior curvature of the acromion; insert the needle perpendicular to the skin and tilt slightly upwards.

**Posterior approach** (Fig. 6, page 34).

*Landmarks*

- Inferior margin of the posterolateral portion of the acromion; insert the needle perpendicular to the skin, about 1 cm below this margin, then tilt the needle slightly upwards and medially.

### 2. TENDINOPATHY OF THE LONG HEAD OF THE BICEPS BRACHII

**Approach along the course of the tendon** (Fig. 7, page 34).

*Landmarks*

- With the elbow extended and the upper limb externally-rotated, palpate the tendon at the bicipital groove; insert the needle with a slight upward tilt (if resistance is felt on injection, retract the needle about 2 mm).

### 3. CAPSULITIS

**Anterior approach** (Fig. 8, page 35).

#### *Landmarks*

Insert the needle below the inferior margin of the posterior angle of the acromion, in the direction of the coracoid process, until contact with the humeral cartilage is felt.

## TECHNIQUE

1. Point of greatest tenderness
2. Point of greatest tenderness
3. Point of greatest tenderness

## NEEDLES

1. 22G x 32 mm
2. 26G x 13 mm on the tendon
3. 22G x 32 mm

**LANDMARKS AND APPROACHES - FIGURES**

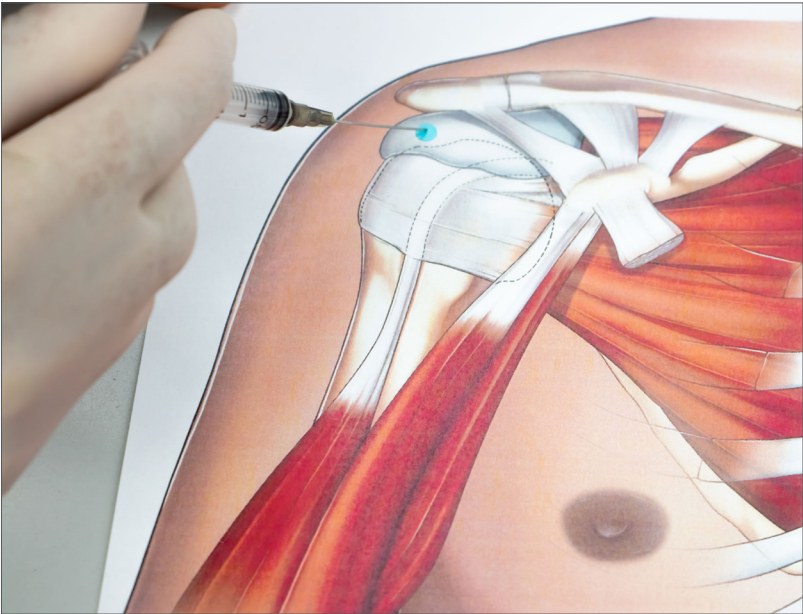


Fig. 4: Rotator cuff tendinopathy - **anterior approach**.

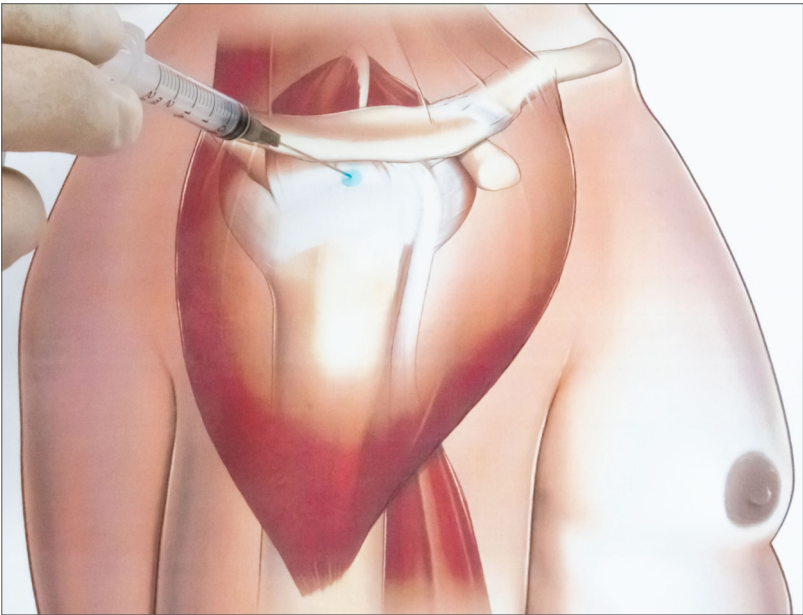


Fig. 5: Rotator cuff tendinopathy - **lateral approach**.

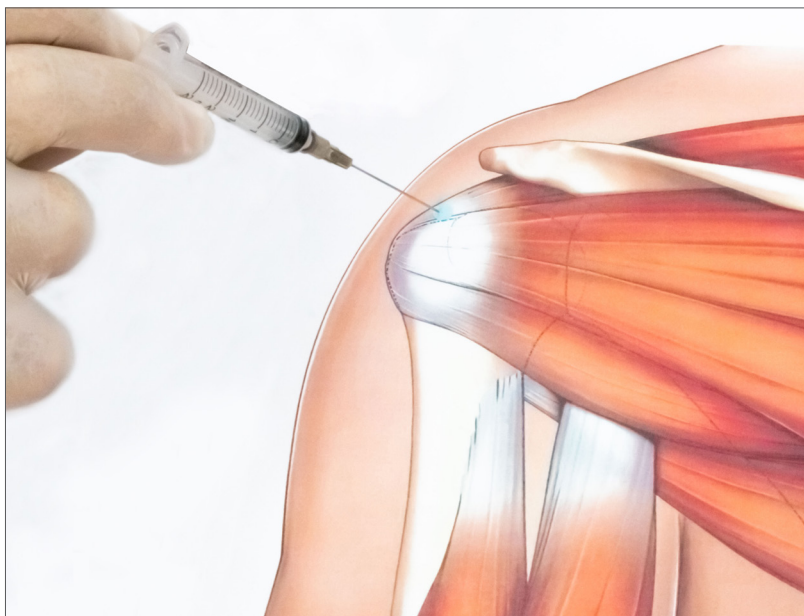

Fig. 6: Rotator cuff tendinopathy - **posterior approach**.

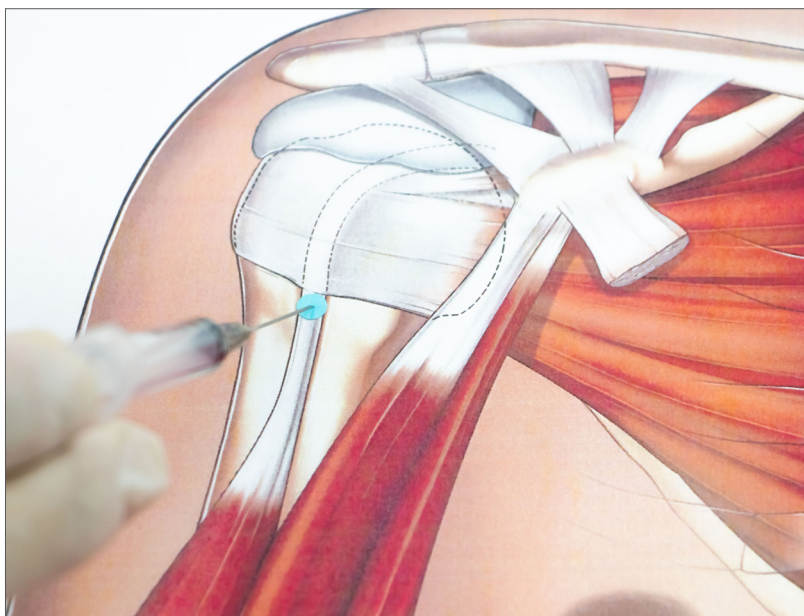


Fig. 7: Tendinopathy of the long head of the biceps brachii - **approach along the course of the tendon**.

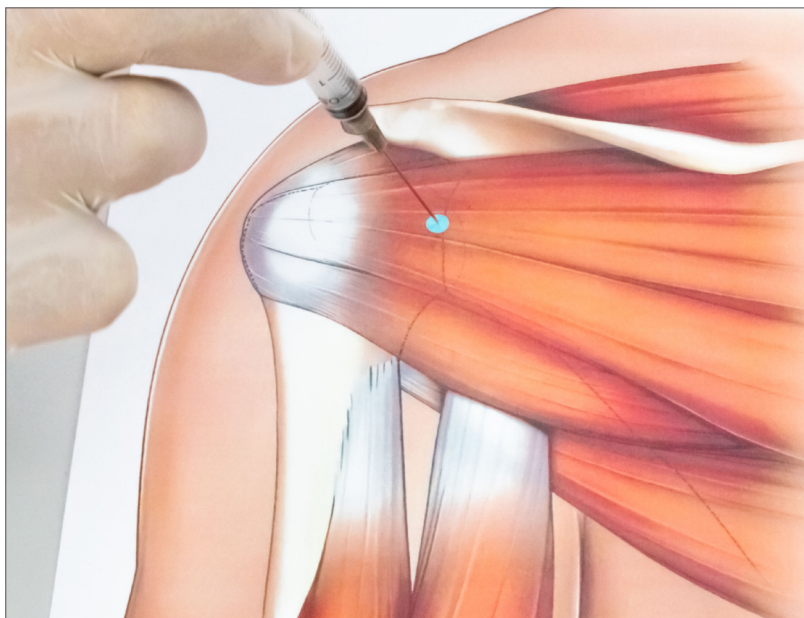
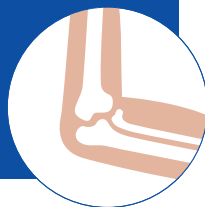

Fig. 8: Capsulitis - **anterior approach**.



# ELBOW



## SOFT TISSUE DISORDERS

Disorders secondary to ageing, postural defects and overload, trauma, and injury, such as:

1. EPICONDYLITIS
2. MEDIAL EPICONDYLITIS

### MD

1. MD-TISSUE
2. MD-TISSUE

### PATIENT POSITION

1. Sitting or supine
2. Sitting or supine

### LANDMARKS/ APPROACHES

#### 1. EPICONDYLITIS

Epicondylar eminence, with elbow flexed to 90°.

Insert the needle at an angle of approximately 30° to the skin plane, in a proximodistal direction. Distribute the product while turning the needle through approximately 180° (Fig. 9, page 38).

#### 2. MEDIAL EPICONDYLITIS

Epitrochlear eminence, with the elbow flexed to 90° and the limb externally rotated. Insert the needle at an angle of approximately 30° to the skin plane, in a proximodistal direction. Distribute the product while turning the needle through approximately 180°, remaining within the volar portion of the epitrochlea to avoid the ulnar nerve (Fig. 10, page 38).



## TECHNIQUE

1. Injection at the point of greatest tenderness
2. Injection at the point of greatest tenderness

## NEEDLES

1. 26G x 13 mm
2. 26G x 13 mm

## Literature on Collagen Medical Devices in the disorders of the **ELBOW** anatomical region

- Ahumada Arredondo O. – Epicondylitis – a solution with Collagen Medical Devices. Physiological Regulating Medicine, 2020; 45-55.
- Corrado B. et al. – Treatment of lateral epicondylitis with Collagen Injections: a Pilot Study. Muscles, Ligaments and Tendons Journal 2019;9 (4):584-589.

**LANDMARKS AND APPROACHES - FIGURES**

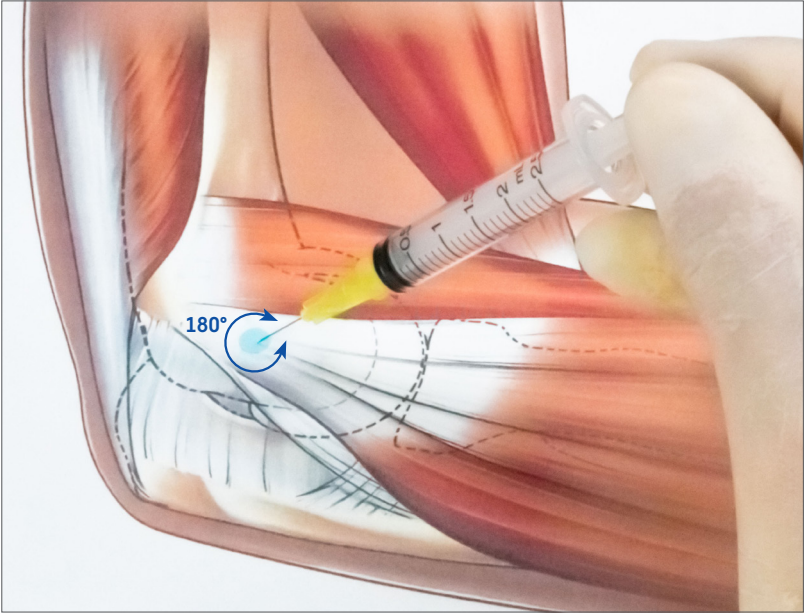


Fig. 9: Epicondylitis.

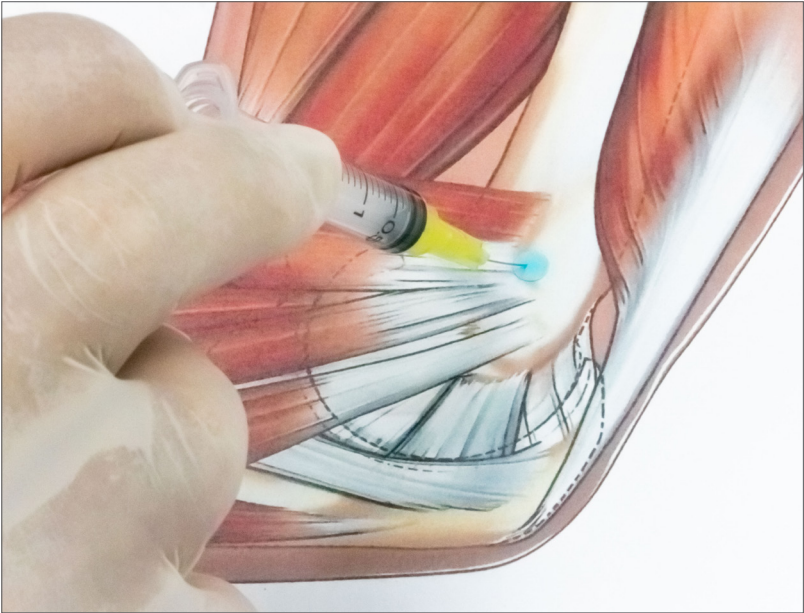
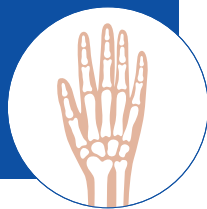

Fig. 10: Medial epicondylitis.

# HAND/WRIST



## OSTEOARTICULAR DISORDERS

Disorders secondary to ageing, postural defects and overload, trauma, and injury, such as:

1. **RHIZARTHRISIS (TRAPEZIOMETACARPAL OSTEOARTHRITIS)**
2. **METACARPOPHALANGEAL OSTEOARTHRITIS**
3. **PROXIMAL INTERPHALANGEAL OSTEOARTHRITIS**

### MD

1. MD-SMALL JOINTS
2. MD-SMALL JOINTS
3. MD-SMALL JOINTS

### PATIENT POSITION

1. Sitting or supine
2. Sitting or supine
3. Sitting or supine

### LANDMARKS/ APPROACHES

1. **RHIZARTHRISIS (TRAPEZIOMETACARPAL OSTEOARTHRITIS)**  
Trapeziometacarpal joint line (Fig. 11, page 41).
2. **METACARPOPHALANGEAL OSTEOARTHRITIS**  
Metacarpophalangeal joint line (Fig. 12, page 41).
3. **PROXIMAL INTERPHALANGEAL OSTEOARTHRITIS**  
Proximal interphalangeal (PIP) joint line (Fig. 13, page 42).

## TECHNIQUE

1. Needle perpendicular to the skin, exerting traction on the thumb\*
2. Needle perpendicular to the skin, on the radial or ulnar side, exerting traction on the finger\*
3. Needle perpendicular to the skin, on the radial or ulnar side, exerting traction on the finger\*

---

\* It is also possible to perform the injection at peri-articular level (ulnar and radial side), introducing the needle parallel to the capsular plane.

## NEEDLES

1. 26G x 13 mm
2. 26G x 13 mm
3. 26G x 13 mm

## Literature on Collagen Medical Devices in the disorders of the **HAND/WRIST** anatomical region

- Ottaviani M. – Treatment of joint conditions with Guna Collagen Medical Devices – clinical study on 257 patients. Physiological Regulating Medicine 2018; 18-25.

**LANDMARKS AND APPROACHES - FIGURES**

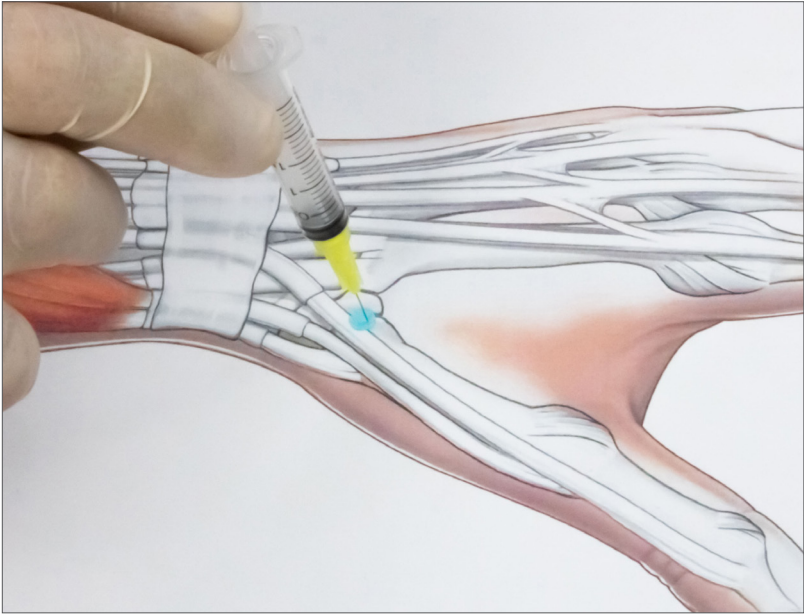


Fig. 11: Rhizarthrosis (trapeziometacarpal osteoarthritis).

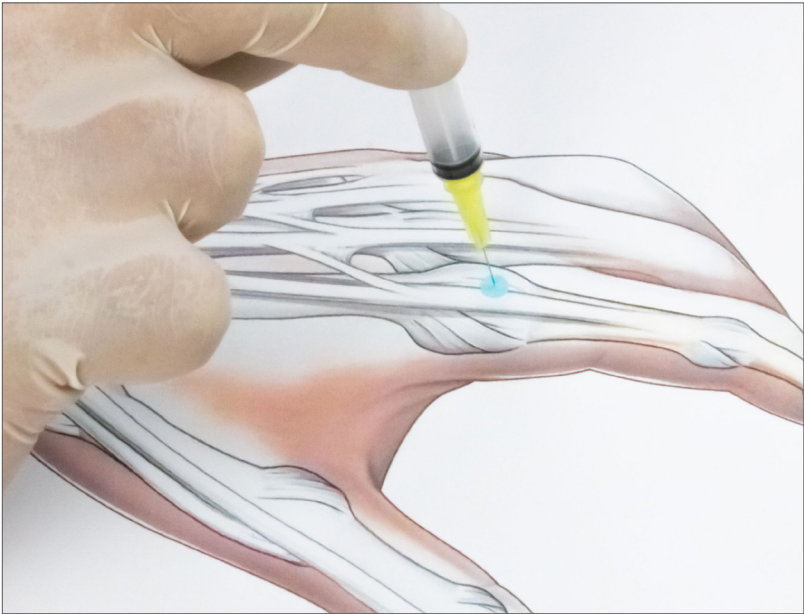


Fig. 12: Metacarpophalangeal osteoarthritis.

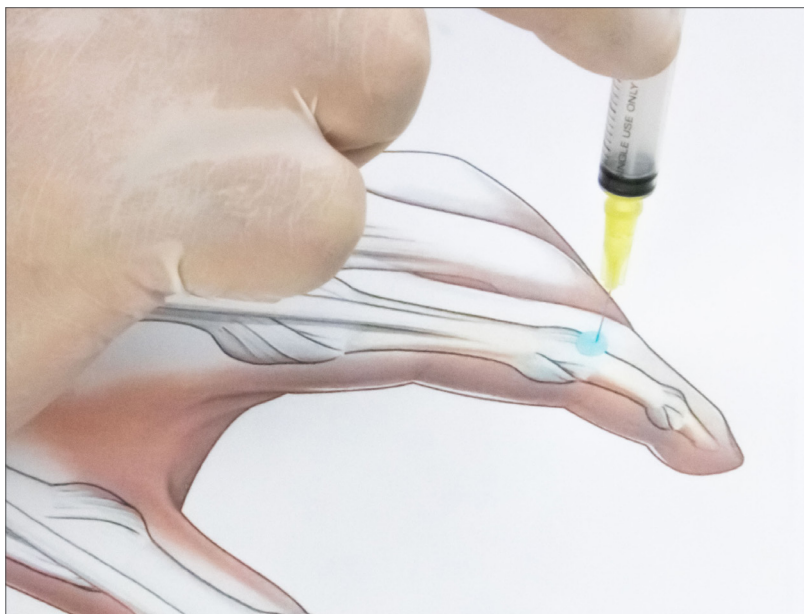

Fig. 13: Proximal interphalangeal osteoarthritis.

# SOFT TISSUE DISORDERS

Disorders secondary to ageing, postural defects and overload, trauma, and injury, such as:

1. **DE QUERVAIN'S TENOSYNOVITIS**
2. **TRIGGER FINGER (STENOSING FLEXOR TENOSYNOVITIS)**
3. **CARPAL TUNNEL SYNDROME**

## MD

1. MD-TISSUE
2. MD-TISSUE
3. MD-NEURAL + MD-TISSUE

## PATIENT POSITION

1. Sitting or supine
2. Sitting or supine
3. Sitting or supine

## LANDMARKS/ APPROACHES

1. **DE QUERVAIN'S TENOSYNOVITIS**  
Radial styloid process (sheath of the short extensor and long abductor of the thumb) (Fig. 14, page 45).
2. **TRIGGER FINGER (STENOSING FLEXOR TENOSYNOVITIS)**  
A1 flexor tendon pulley (Fig. 15, page 45).
3. **CARPAL TUNNEL SYNDROME**  
Tendon of the palmaris longus muscle (found when the wrist is flexed against resistance) (Fig. 16, page 46).

## TECHNIQUE

1. Insert the needle at an angle of approximately  $30^{\circ}$  to the skin plane, in a proximal direction along the tendon.
2. Insert the needle at an angle of approximately  $45^{\circ}$  to the skin plane, in a distoproximal direction.
3. Insert the needle at an angle of approximately  $45^{\circ}$  to the skin plane, in a proximodistal direction.

## NEEDLES

1. 26G x 13 mm
2. 26G x 13 mm
3. 26G x 13 mm



# LANDMARKS AND APPROACHES - FIGURES

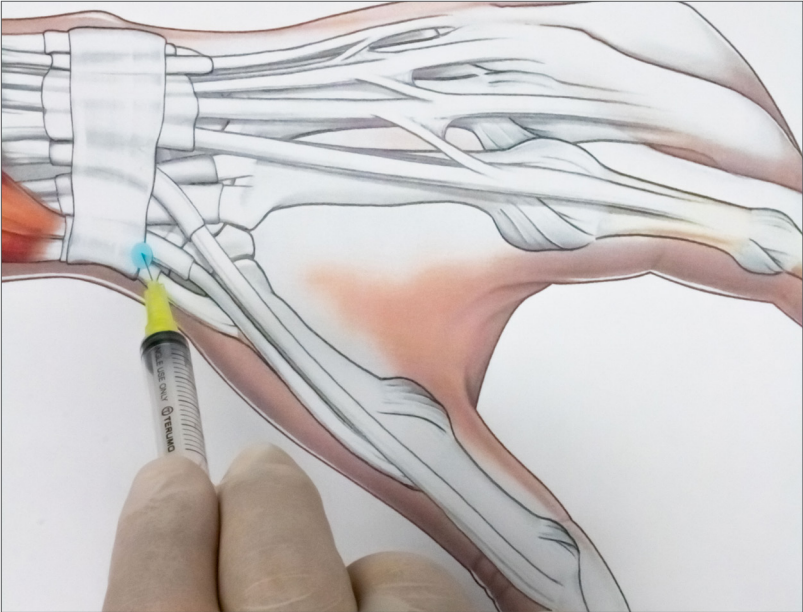


Fig. 14: De Quervain's tenosynovitis.

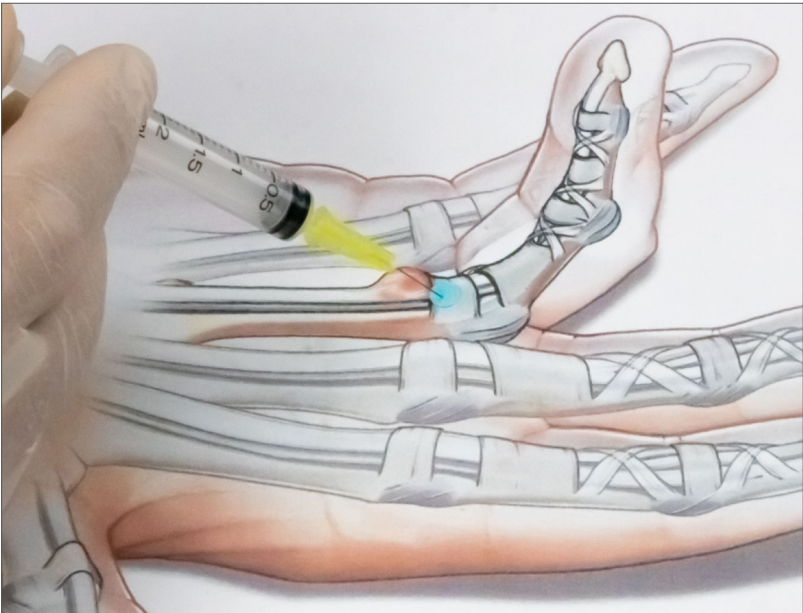


Fig. 15: Trigger finger (stenosing flexor tenosynovitis).

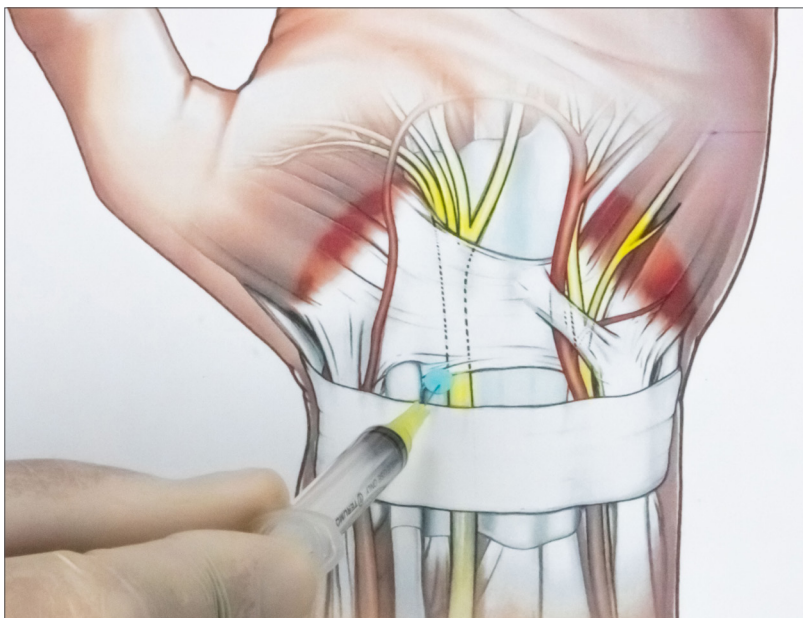
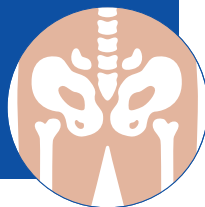


Fig. 16: Carpal tunnel syndrome.

# HIP



## OSTEOARTICULAR DISORDERS

Disorders secondary to ageing, postural defects and overload, trauma, and injury, such as:

### 1. HIP OSTEOARTHRITIS

#### MD

### 1. MD-HIP

#### PATIENT POSITION

### 1. Supine

#### LANDMARKS/ APPROACHES

### 1. HIP OSTEOARTHRITIS

Anterior parasagittal approach. Probe aligned with the neck of the femur - acetabulum axis and head of the femur.

#### TECHNIQUE

1. After disinfection with Iodopovidone, introduce the needle into the anterior recess of the capsule at head of the femur level using an anterosuperior or anteroinferior approach.  
When the needle comes into contact with the head of the femur, retract it by 1-2 mm and inject MD-HIP into the hip joint cavity.

#### NEEDLES

1. 20G x 90 mm spinal needle

## Literature on Collagen Medical Devices in the disorders of the **HIP** anatomical region

- Giovannangeli F. – Intra articular administration of MD HIP in 24 patients affected by symptomatic hip osteoarthritis – A 24-month cohort study. *Physiological Regulating Medicine*, 2017; 31-32.
- Migliore A. et al. – Intra-articular administration of MD-Hip in 7 patients affected by hip osteoarthritis unresponsive to viscosupplementation. Six-month multicenter trial. *Physiological Regulating Medicine*, 2013; 31. Clinical trial presented at the International Symposium Intra Articular Treatment; Rome (October 2011).
- Milano E. – The role of MD-HIP In ultrasound-guided injection therapy for osteoarthritis of the hip. *Physiological Regulating Medicine*, 2018; 3-8.
- Ottaviani M. – Treatment of joint conditions with Guna Collagen Medical Devices – clinical study on 257 patients. *Physiological Regulating Medicine* 2018; 18-25.
- Tivchev P. – Efficacy of injections MD-Hip and MD-Matrix in the treatment of coxarthrosis. *Clinical and ultrasonographic evaluation. Bul. J. Ortop. Trauma. Vol. 49, 3-2012.*

# SOFT TISSUE DISORDERS

Disorders secondary to ageing, postural defects and overload, trauma and injury, such as:

1. **GREATER TROCHANTERIC PAIN SYNDROME**
2. **TROCHANTERIC BURSITIS**
3. **ADDUCTOR ENTHESITIS**

## MD

1. MD-TISSUE
2. MD-TISSUE
3. MD-TISSUE

## PATIENT POSITION

1. Lateral decubitus
2. Lateral decubitus
3. Supine, knee flexed, hip abducted and externally rotated

## LANDMARKS/ APPROACHES

1. **GREATER TROCHANTERIC PAIN SYNDROME**  
Apex of the greater trochanter (Fig. 17, page 51).
2. **TROCHANTERIC BURSITIS**  
Apex/inferior margin of the greater trochanter (Fig. 18, page 51).
3. **ADDUCTOR ENTHESITIS**  
Palpation of the adductor longus tendon at the proximal insertion (Fig. 19, page 52).

## TECHNIQUE

1. From the point of greatest tenderness, perform 2-3 injections, approximately 2 cm apart, with the needle perpendicular to the skin.
2. At the point of greatest tenderness, with the needle perpendicular to the skin.
3. At the point of greatest tenderness, with the needle at an angle of approximately 20°-30° to the skin plane, inject while performing a fan-shaped movement.

## NEEDLES

1. 22G x 32 mm
2. 22G x 32 mm
3. 26G x 13 mm

**LANDMARKS AND APPROACHES - FIGURES**

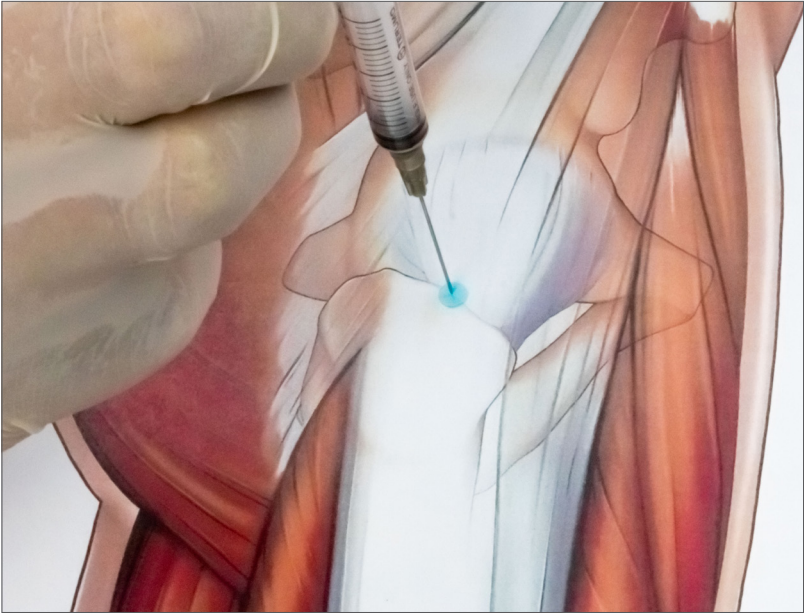


Fig. 17: Greater trochanteric pain syndrome.

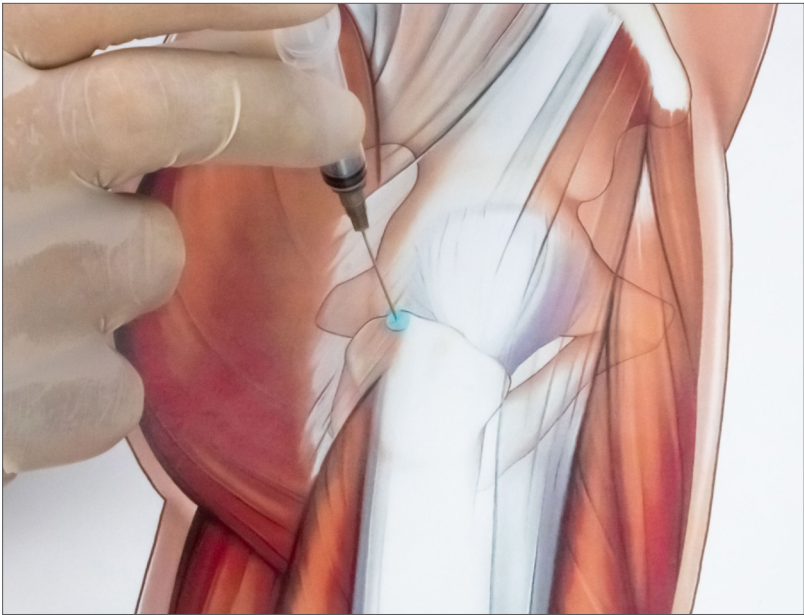


Fig. 18: Trochanteric bursitis.

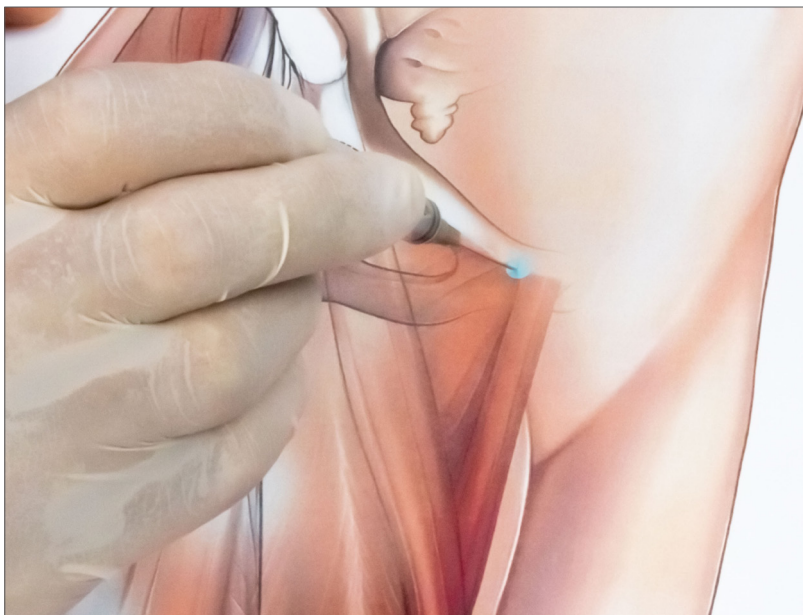



Fig. 19: Adductor enthesitis.



# THIGH



## SOFT TISSUE DISORDERS

Disorders secondary to ageing, postural defects and overload, trauma, and injury, such as:

1. FASCIA LATA DISORDERS
2. QUADRICEPS MUSCLE INJURY/INFLAMMATION
3. FLEXOR MUSCLE INJURY/INFLAMMATION
4. PIRIFORMIS SYNDROME

## MD

1. MD-TISSUE
2. MD-TISSUE or MD-MUSCLE
3. MD-TISSUE or MD-MUSCLE
4. MD-MUSCLE

## PATIENT POSITION

1. Lateral decubitus
2. Supine
3. Prone
4. Prone

## LANDMARKS/ APPROACHES

### 1. FASCIA LATA DISORDERS

Point of greatest tenderness along the course of the fascia lata (Fig. 20, page 56).

### 2. QUADRICEPS MUSCLE INJURY/INFLAMMATION

Point of greatest muscle tenderness (Fig. 21, page 56).

### 3. FLEXOR MUSCLE INJURY/INFLAMMATION

Point of greatest muscle tenderness (Fig. 22, page 57).

### 4. PIRIFORMIS SYNDROME

Point of greatest muscle tenderness (along lateral sacral margin).

## TECHNIQUE

1. From the point of greatest tenderness, perform 2-3 injections, approximately 2-4 cm apart, with the needle perpendicular to the skin.

2. From the point of greatest tenderness, perform 2-3 injections, approximately 2-4 cm apart, with the needle perpendicular to the skin.

3. From the point of greatest tenderness, perform 2-3 injections, approximately 2-4 cm apart, with the needle perpendicular to the skin.

4. **ULTRASOUND-GUIDED TECHNIQUE:** Draw a line between the 'dimple of Venus' of the sacroiliac joint and the greater trochanter. Halfway between the two points, draw a perpendicular 5 cm segment with a caudal direction. Position the ultrasound probe over the marked point and move it towards the sacrum to examine both the piriformis muscle and the greater sciatic nerve. Under ultrasound guidance, progress the 20G x 90 mm spinal needle in a mid-lateral direction, passing just lateral to the lateral sacral margin, until the piriformis muscle has been penetrated.

## NEEDLES

1. 26G x 13 mm
2. 26G x 13 mm
3. 26G x 13 mm
4. 22G x 90 mm spinal needle

## Literature on Collagen Medical Devices in the disorders of the **THIGH** anatomical region

- Staňa J. – 3 years Inluhacovice spa with Collagen Medical Devices injections in the treatment of piriformis syndrome. Physiological Regulating Medicine, 2016-2017:19-20.

**LANDMARKS AND APPROACHES - FIGURES**

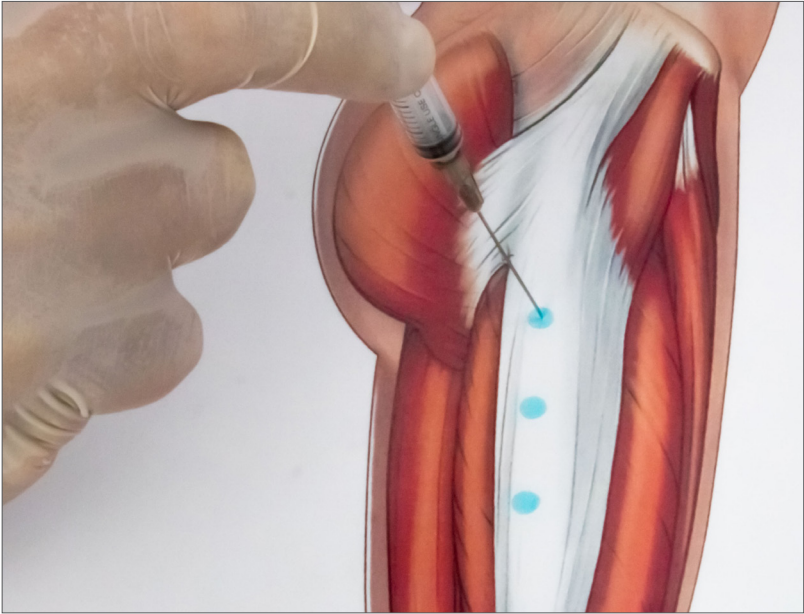


Fig. 20: Fascia lata disorders (inject at all indicated points).

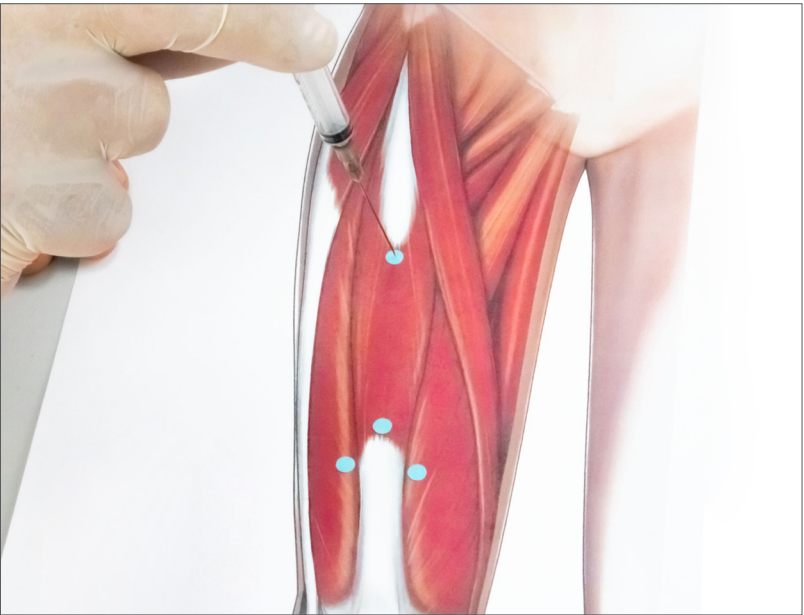


Fig. 21: Quadriceps muscle injury/inflammation (inject at all indicated points).

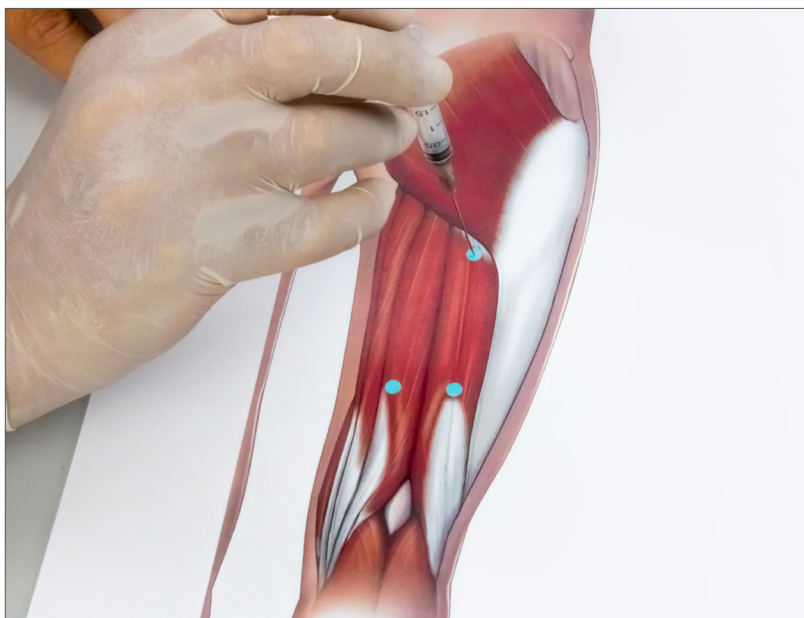


Fig. 22: Flexor muscle injury/inflammation (inject at all indicated points).

# KNEE



## OSTEOARTICULAR DISORDERS

Disorders secondary to ageing, postural defects and overload, trauma, and injury, such as:

1. FEMOROTIBIAL/PATELLOFEMORAL OSTEOARTHRITIS OF THE KNEE
2. PATELLOFEMORAL CHONDROPATHY
3. ARTHROSYNOVITIS

### MD

1. MD-KNEE
2. MD-KNEE
3. MD-KNEE

### PATIENT POSITION

1. Supine, knee flexed
2. Supine, knee flexed
3. Supine, knee flexed

### LANDMARKS/ APPROACHES

1. FEMOROTIBIAL/ PATELLOFEMORAL OSTEOARTHRITIS OF THE KNEE

Triangular shaped area defined by the margin of the patellar tendon, margin of the femoral condyle and superior margin of the tibial plateau (both medial and lateral sides) (Fig. 23, page 60).

## 2. PATELLOFEMORAL CHONDROPATHY

Triangular shaped area defined by the margin of the patellar tendon, margin of the femoral condyle and superior margin of the tibial plateau (both medial and lateral sides)  
(Fig. 23, page 60).

## 3. ARTHROSYNOVITIS

Triangular shaped area defined by the margin of the patellar tendon, margin of the femoral condyle and superior margin of the tibial plateau (both medial and lateral sides)  
(Fig. 23, page 60).

## TECHNIQUE

Insert the needle in the middle of this area, keeping it parallel to the tibial plateau and at an angle of approximately 45° to the frontal plane.

## NEEDLES

1. 22G x 32 mm
2. 22G x 32 mm
3. 22G x 32 mm

## Literature on Collagen Medical Devices in the disorders of the **KNEE** anatomical region

- Boshnakov D. – Application and assessment of efficacy of collagen injections Guna MDs in gonarthrosis. Physiological Regulating Medicine, 2013; 29-30.
- Martin Martin L.S. et al. – A double blind randomized active-controlled clinical trial on the intra-articular use of MD-KNEE versus sodium hyaluronate in patients with knee osteoarthritis ("Joint"). BMC Musculoskeletal Disorders, 2016; 17-94.

- Nestorova R. et al. – Efficiency of Collagen Injections "Guna MDs" In Patients With Gonarthrosis, Assessed Clinically And By Ultrasound. Conference paper published in Osteoporosis International (2012) 23: (Suppl 2): S85–S386 (IF 3.96).
- Ottaviani M. – Treatment of joint conditions with Guna Collagen Medical Devices – clinical study on 257 patients. Physiological Regulating Medicine 2018; 18-25.
- Reshkova V. et al. – Efficacy and safety evaluation of Guna Collagen MDs injections in knee osteoarthritis – A case series of 30 patients. European Journal of Musculoskeletal Diseases - Vol. 2, no. 2, 79-82 (2013).

## LANDMARKS AND APPROACHES - FIGURES

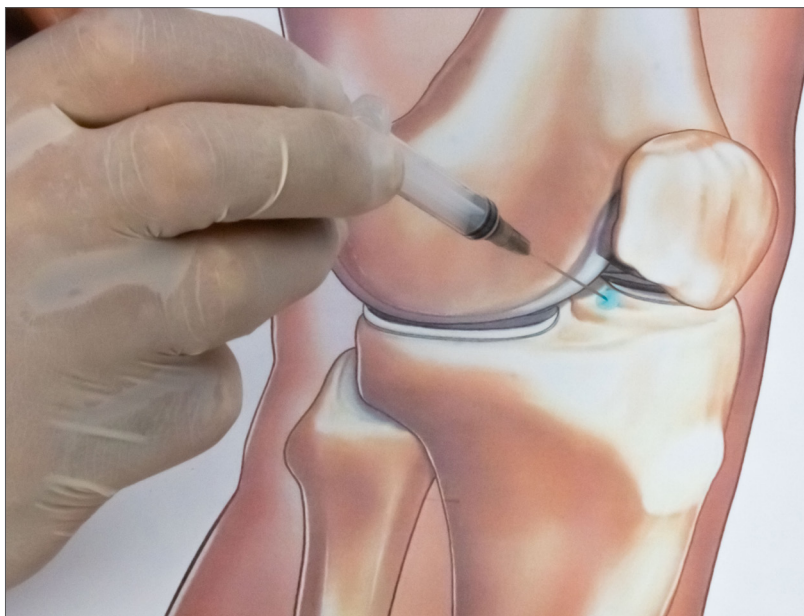


Fig. 23: Femorotibial/patellofemoral osteoarthritis of the knee; Patellofemoral chondropathy; Arthrosynovitis.



# SOFT TISSUE DISORDERS

Disorders secondary to ageing, postural defects and overload, trauma and injury, such as:

1. ILIOTIBIAL BAND SYNDROME
2. TENDINOPATHY (QUADRICEPS/PATELLA - HAMSTRINGS)
3. LIGAMENT INJURY
4. MENISCAL DISORDERS

## MD

1. MD-TISSUE
2. MD-TISSUE
3. MD-KNEE
4. MD-KNEE

## PATIENT POSITION

1. Supine, knee flexed
2. Supine, knee flexed/extended
3. Supine, knee flexed
4. Supine, knee flexed

## LANDMARKS/ APPROACHES

1. ILIOTIBIAL BAND SYNDROME  
Point of greatest tenderness (Fig. 24, page 63).
2. TENDINOPATHY (OF THE QUADRICEPS/ PATELLAR – HAMSTRINGS)  
Point of greatest tenderness (Figs. 25-26, pages 63-64).
3. LIGAMENT INJURY  
Point of greatest tenderness (Fig. 27, page 64).
4. MENISCAL DISORDERS  
Point of greatest tenderness (Fig. 28, page 65).

## TECHNIQUE

1. Inject at the point of greatest tenderness; with the needle perpendicular to the skin.
2. Inject at the point of greatest tenderness; with the needle perpendicular to the skin.
3. Inject at the point of greatest tenderness; with the needle perpendicular to the skin.
4. Inject at the point of greatest tenderness; with the needle perpendicular to the skin.

## NEEDLES

1. 26G x 13 mm
2. 26G x 13 mm
3. 26G x 13 mm
4. 26G x 13 mm

**LANDMARKS AND APPROACHES - FIGURES**

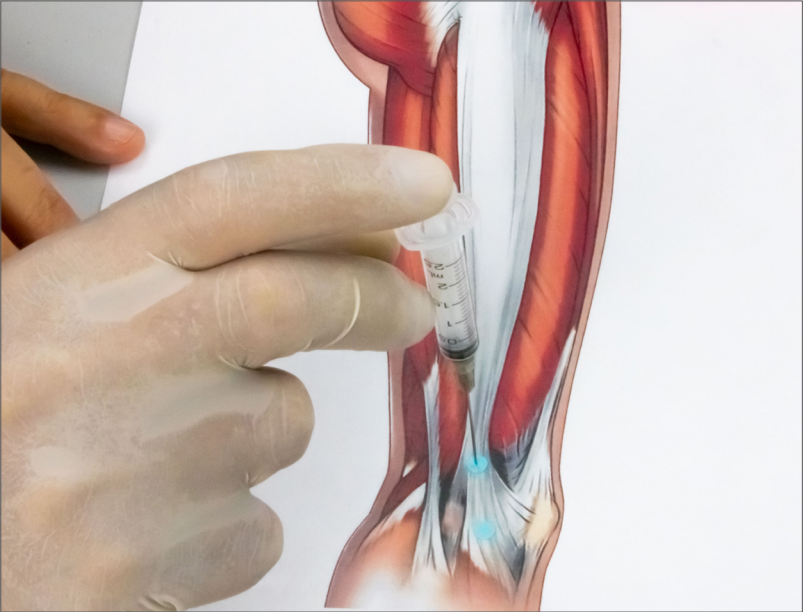


Fig. 24: Iliotibial band syndrome (inject at all indicated points).

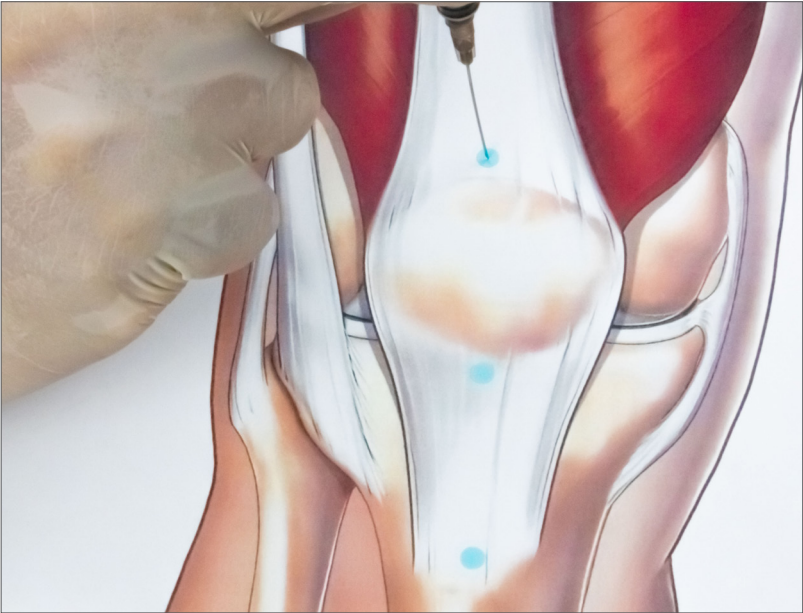


Fig. 25: Quadriceps/ patellar tendinopathy (inject at all indicated points).

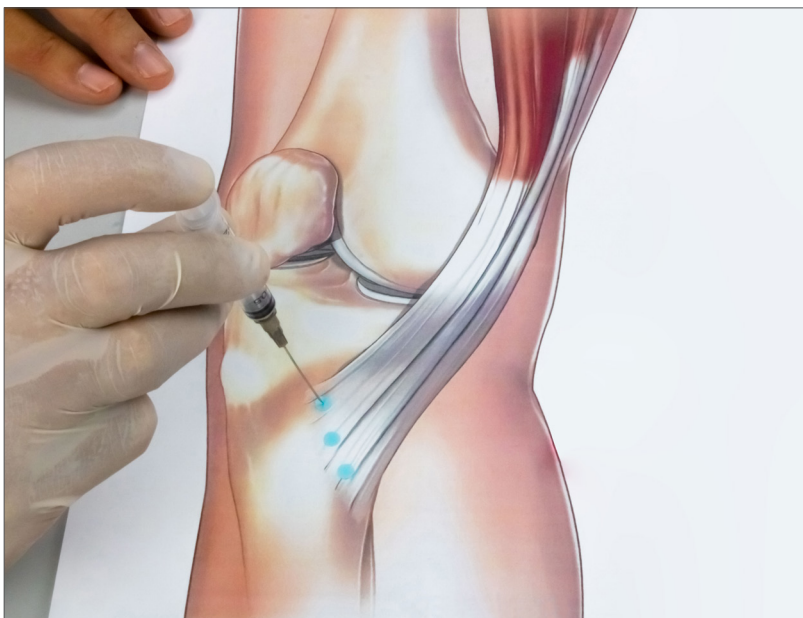


Fig. 26: Hamstrings tendinopathy (inject at all indicated points).

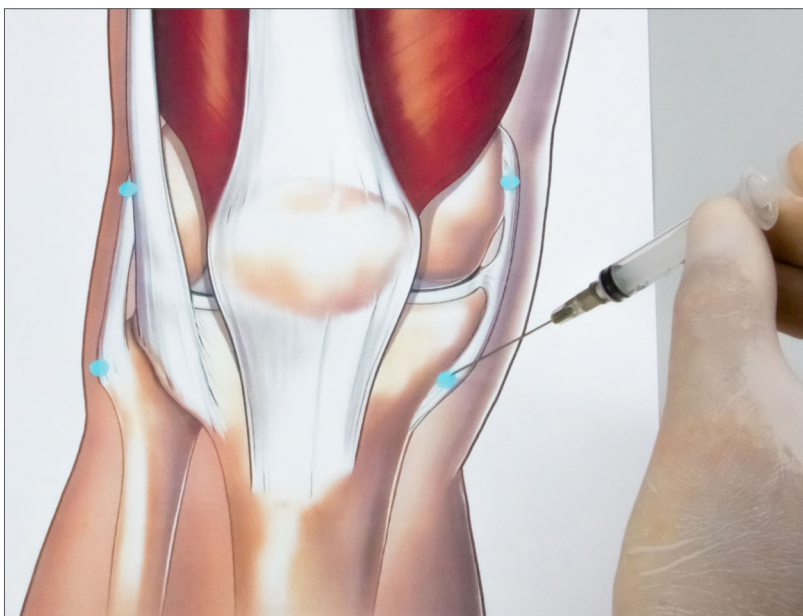


Fig. 27: Ligament injury (inject at all indicated points).

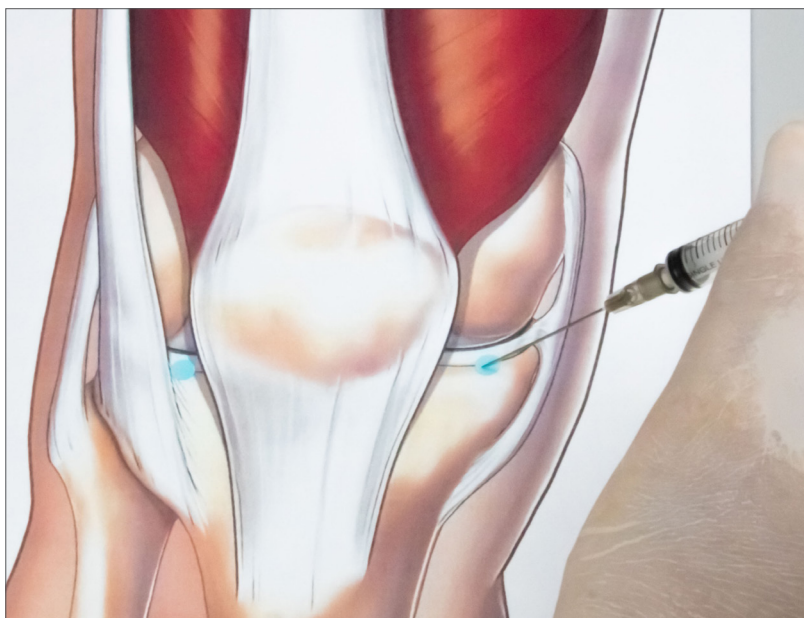
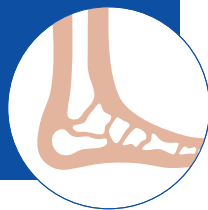
Fig. 28: Meniscal disorders (inject at all indicated points).

# ANKLE



## OSTEOARTICULAR DISORDERS

Disorders secondary to ageing, postural defects and overload, trauma and injury, such as:

### 1. OSTEOARTHRITIS

#### MD

#### 1. MD-SMALL JOINTS

#### PATIENT POSITION

#### 1. Supine

#### LANDMARKS/ APPROACHES

#### 1. OSTEOARTHRITIS

Most lateral portion of the tibiofibulotalar joint (approximately one transverse finger's width proximal and medial to the apex of the lateral malleolus) (Fig. 29, page 67).

#### TECHNIQUE

#### 1. Needle perpendicular to the skin plane at an angle of approximately 30° in a lateromedial direction; insert carefully until joint space is felt.

#### NEEDLES

#### 1. 22G x 32 mm

## Literature on Collagen Medical Devices in the disorders of the **ANKLE** anatomical region

- Ottaviani M. – Treatment of joint conditions with Guna Collagen Medical Devices – Clinical study on 257 patients. Physiological Regulating Medicine 2018; 18-25.

### LANDMARKS AND APPROACHES - FIGURES

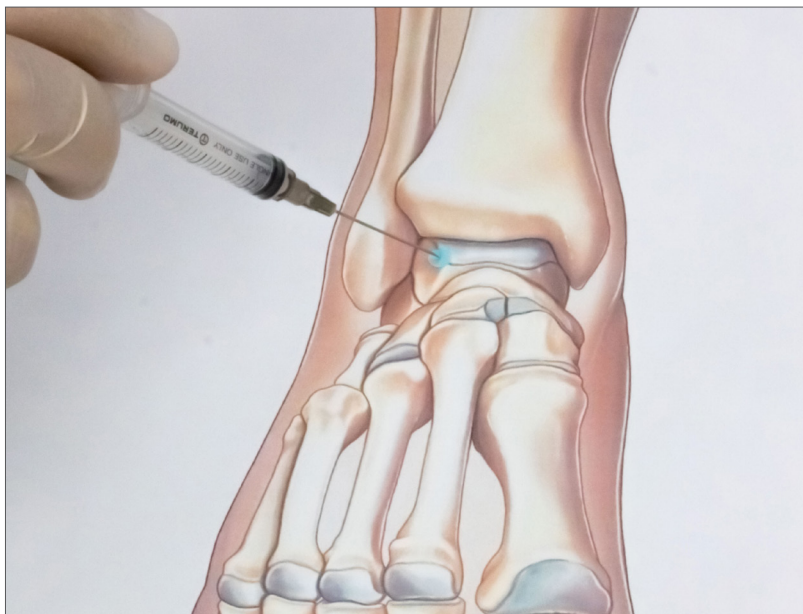

Fig. 29: Osteoarthritis.

# SOFT TISSUE DISORDERS

Disorders secondary to ageing, postural defects and overload, trauma, and injury, such as:

1. **ACHILLES' TENDONITIS/TENDINOSIS**
2. **LATERAL AND MEDIAL CAPSULOLIGAMENTOUS INJURY/INFLAMMATION**

## MD

1. MD-TISSUE
2. MD-TISSUE

## PATIENT POSITION

1. Prone (with foot beyond the end of the couch)
2. Supine

## LANDMARKS/ APPROACHES

1. **ACHILLES' TENDONITIS/TENDINOSIS**  
Medial and lateral margin of the tendon  
(Fig. 30, page 70).
2. **LATERAL AND MEDIAL CAPSULOLIGAMENTOUS INJURY/INFLAMMATION**  
Medial/lateral perimalleolar area  
(Fig. 31, page 70).



## TECHNIQUE

1. At the most tender point, identify 2 points approximately 2 cm from one another, on the lateral and medial margin of the tendon; insert the needle at an angle of approximately 30° (medially for medial points and laterally for lateral points). Inject 0.5 mL into each of the four points.
2. Injection at the point of greatest tenderness, at a distance of 5 mm from the malleolar apex. Insert the needle perpendicular to the skin plane.

## NEEDLES

1. 26G x 13 mm
2. 26G x 13 mm

**LANDMARKS AND APPROACHES - FIGURES**

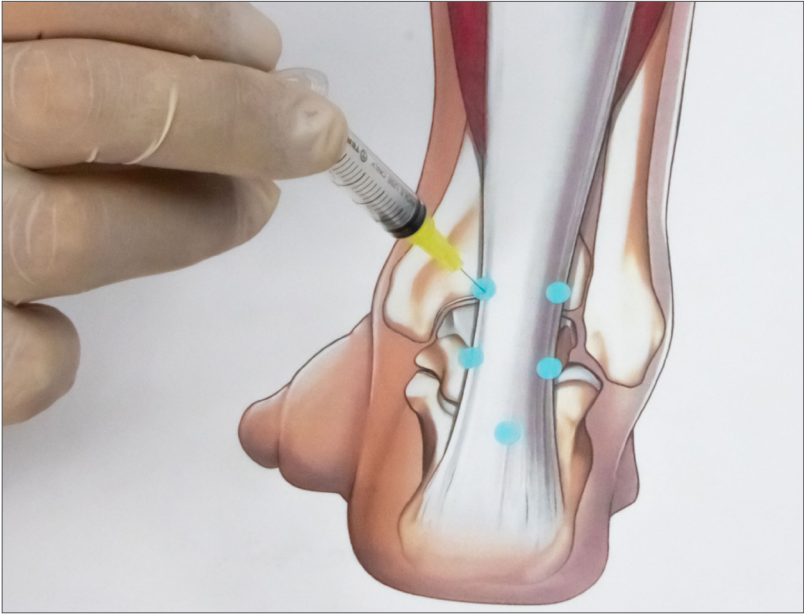


Fig. 30: Achilles' tendonitis/tendinosis (inject at all indicated points).

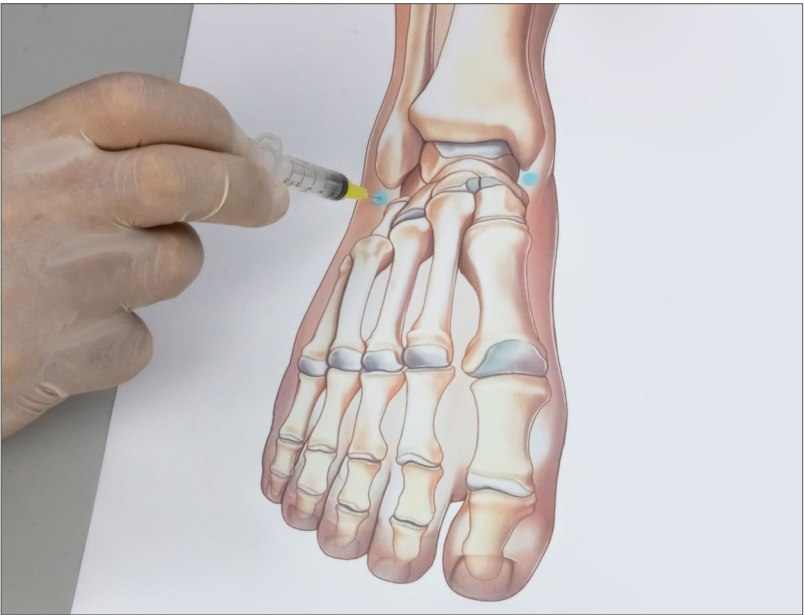
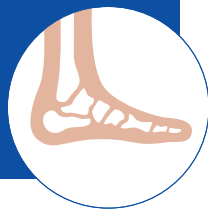
Fig. 31: Lateral and medial capsuloligamentous injury/inflammation (inject at all indicated points).

# FOOT



## OSTEOARTICULAR DISORDERS

Disorders secondary to ageing, postural defects and overload, trauma, and injury, such as:

### 1. METATARSOPHALANGEAL JOINT PAIN

#### MD

#### 1. MD-SMALL JOINTS

#### PATIENT POSITION

#### 1. Supine

#### LANDMARKS/ APPROACHES

#### 1. METATARSOPHALANGEAL JOINT PAIN

Metatarsophalangeal joint line (Fig. 32, page 72).

#### TECHNIQUE

#### 1. Keeping the fingers hyperflexed, insert the needle perpendicular to the skin plane.

#### NEEDLES

#### 1. 26G x 13 mm

## Literature on Collagen Medical Devices in the disorders of the **FOOT** anatomical region

- Corrado B., Bonini I., Tarantino D., Sirico F. – Ultrasound-guided collagen injections for treatment of plantar fasciopathy in runners: A pilot study and case series. *Journal of Human Sport and Exercise*, Sept 2020, 15(3proc), S793-S805.
- Presti C.A. – Medical Devices a base di collagene suino e sostanze ancillari nel trattamento iniettivo della fascite plantare. *Advanced Therapies*. Issue 8 – 2015, available online at <http://www.advancedtherapies.it/2015/04/>.

## LANDMARKS AND APPROACHES - FIGURES

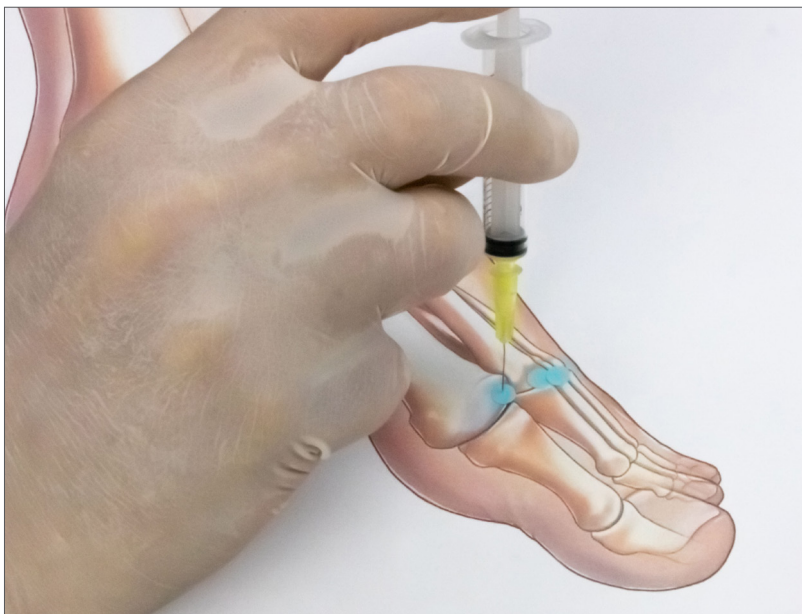

Fig. 32: Metatarsophalangeal joint pain (inject at all indicated points).

# SOFT TISSUE DISORDERS

Disorders secondary to ageing, postural defects and overload, trauma, and injury, such as:

1. ANTERIOR TIBIAL TENDINOPATHY
2. POSTERIOR TIBIAL TENDINOPATHY
3. PERONEAL TENDINOPATHY
4. PLANTAR FASCIITIS AND CALCANEAL SPURS
5. RETROCALCANEAL BURSITIS
6. MORTON'S NEUROMA

## MD

1. MD-TISSUE
2. MD-TISSUE
3. MD-TISSUE
4. MD-TISSUE
5. MD-TISSUE
6. MD-NEURAL

## PATIENT POSITION

1. Supine, foot externally rotated
2. Supine, foot externally rotated
3. Supine, foot internally rotated
4. Supine, foot externally rotated
5. Prone
6. Supine, knee flexed, sole of foot fully supported

## LANDMARKS/ APPROACHES

### 1. ANTERIOR TIBIAL TENDINOPATHY

Along the course or at the insertion of the tendon (Fig. 33, page 76).

### 2. POSTERIOR TIBIAL TENDINOPATHY

Along the course or at the insertion of the tendon (Fig. 34, page 76).

### 3. PERONEAL TENDINOPATHY

Along the course or at the insertion of the tendon (fibularis brevis) (Fig. 35, page 77).

### 4. PLANTAR FASCIITIS AND CALCANEAL SPURS

Insertion of the plantar fascia (Fig. 36, page 77).

### 5. RETROCALCANEAL BURSITIS

Medial process of the calcaneal tuberosity (Fig. 37, page 78).

### 6. MORTON'S NEUROMA

3rd (or 2nd) intermetatarsal space (Fig. 38, page 78).

## TECHNIQUE

1. Insert the needle at an angle of  $10^{\circ}$ - $20^{\circ}$  to the skin plane at the point of greatest tenderness.
2. Insert the needle at an angle of  $10^{\circ}$ - $20^{\circ}$  to the skin plane at the point of greatest tenderness.
3. Insert the needle at an angle of  $10^{\circ}$ - $20^{\circ}$  to the skin plane at the point of greatest tenderness.
4. Insert the needle perpendicular to the skin at the point of greatest tenderness, approximately 2 cm from the plantar skin surface.
5. Insert the needle from the medial or lateral aspect of the calcaneal tuberosity, parallel to the skin plane.
6. Insert the needle at an angle of  $45^{\circ}$ , in a proximodistal direction, into the space between the heads of the metatarsal bones.

## NEEDLES

1. 26G x 13 mm
2. 26G x 13 mm
3. 26G x 13 mm
4. 26G x 13 mm
5. 26G x 13 mm
6. 26G x 13 mm

**LANDMARKS AND APPROACHES - FIGURES**

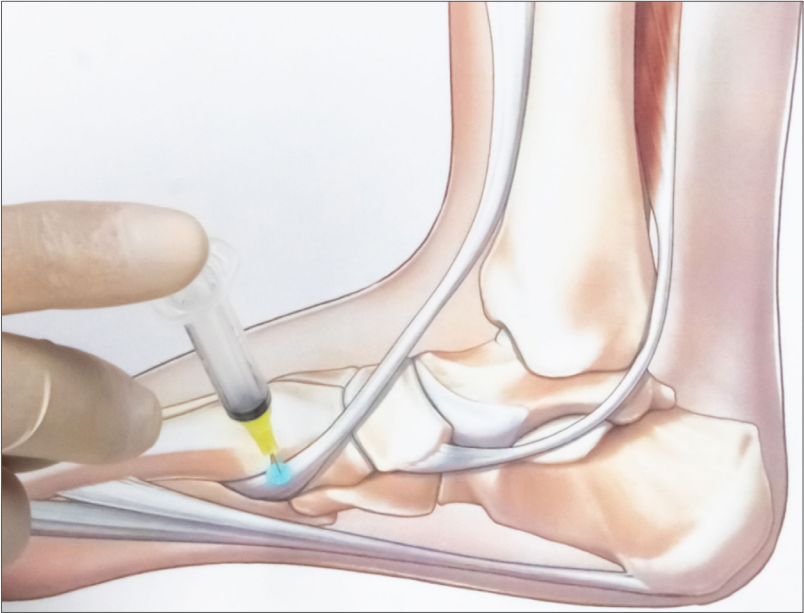


Fig. 33: Anterior tibial tendinopathy.

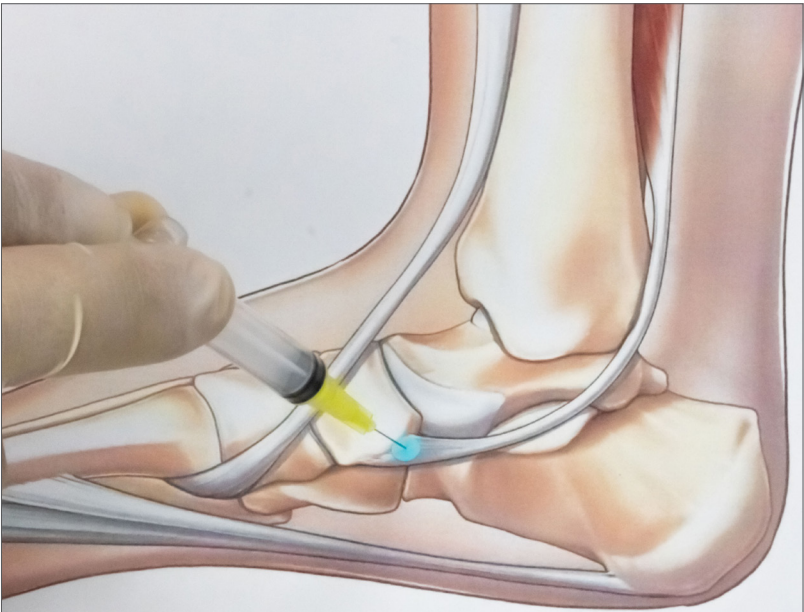


Fig. 34: Posterior tibial tendinopathy.



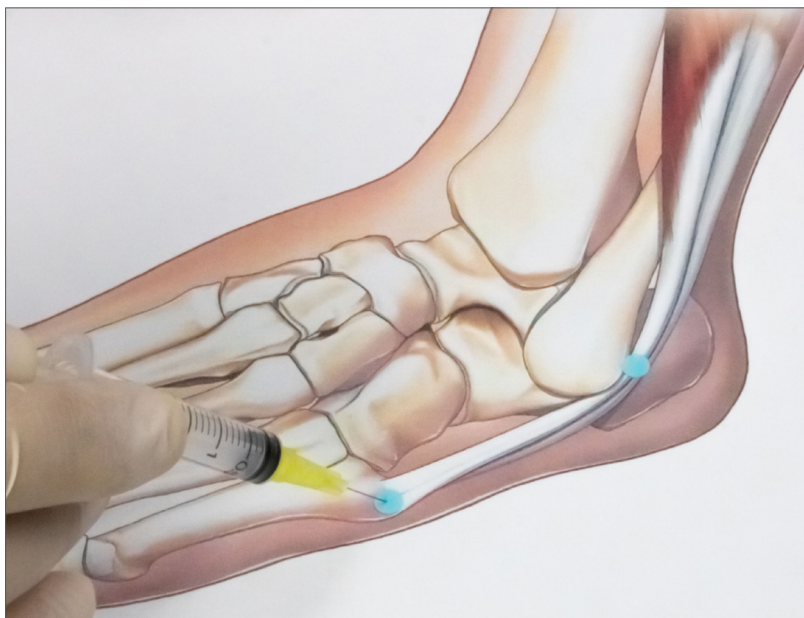


Fig. 35: Peroneal tendinopathy (inject at all indicated points).

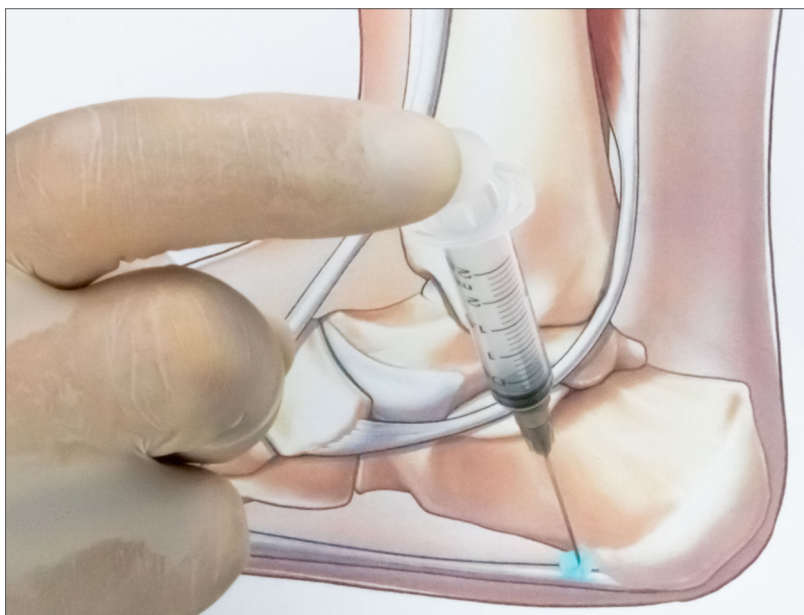


Fig. 36: Plantar fasciitis and calcaneal spurs.

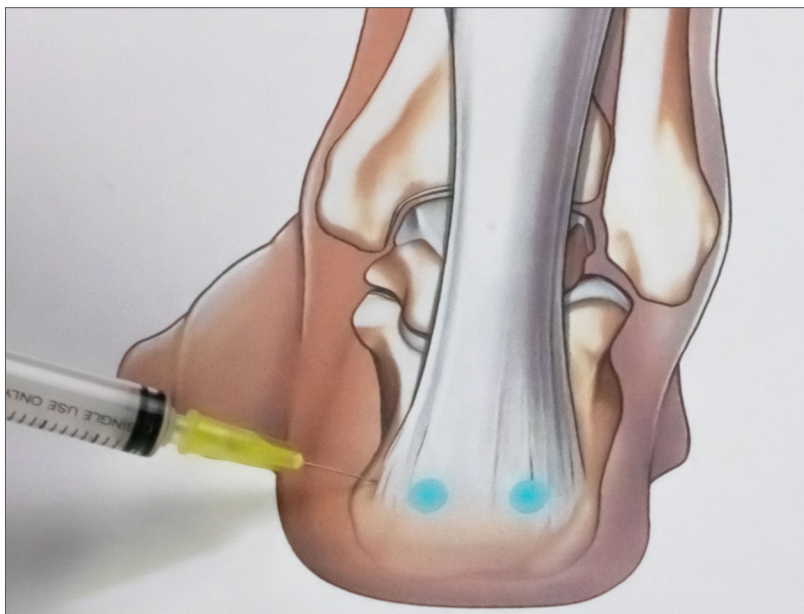


Fig. 37: Retrocalcaneal bursitis (inject at all indicated points).

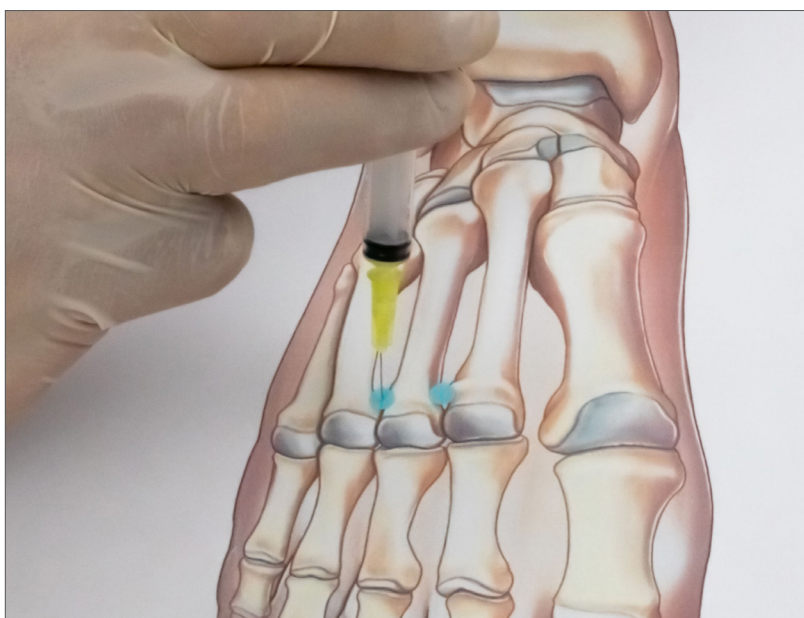


Fig. 38: Morton's neuroma (inject at all indicated points).

## PRODUCTS

# ARTICULAR COLLAGEN MEDICAL DEVICES

## MD-SHOULDER

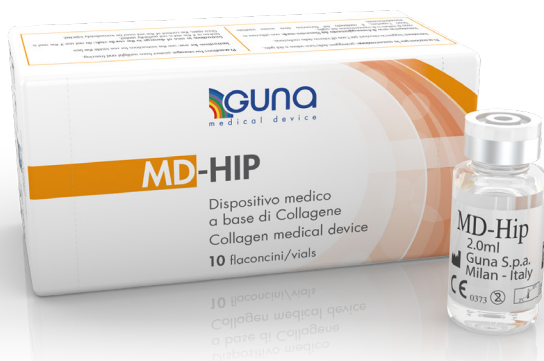Contains Collagen of porcine origin, Iris, NaCl, Water for injection.



It's a CE-marked medical device. Read instructions and warnings before using.

## MD-HIP

Contains Collagen of porcine origin, Calcium phosphate, NaCl, Water for injection.



It's a CE-marked medical device. Read instructions and warnings before using.

## MD-KNEE

Contains Collagen of porcine origin, Arnica, NaCl, Water for injection.



It's a CE-marked medical device. Read instructions and warnings before using.

## MD-SMALL JOINTS

Contains Collagen of porcine origin, Viola, NaCl, Water for injection.



It's a CE-marked medical device. Read instructions and warnings before using.

# NON-ARTICULAR COLLAGEN MEDICAL DEVICES

## MD-TISSUE

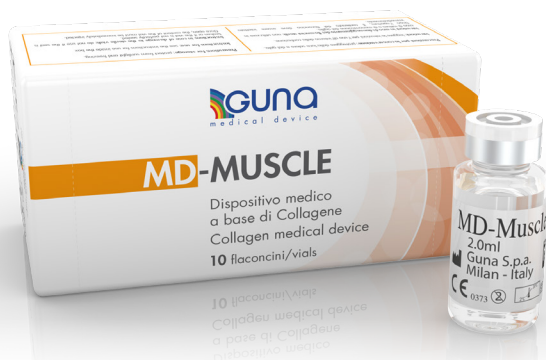Contains Collagen of porcine origin, Ascorbic acid, Magnesium gluconate, Pyridoxine hydrochloride, Riboflavin, Thiamine hydrochloride, NaCl, Water for injection.



It's a CE-marked medical device. Read instructions and warnings before using.

## MD-MUSCLE

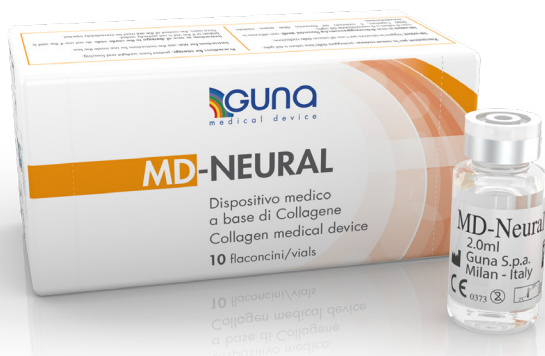Contains Collagen of porcine origin, Hypericum, NaCl, Water for injection.



It's a CE-marked medical device. Read instructions and warnings before using.

# MD-NEURAL

Contains Collagen of porcine origin, Colocynthis, NaCl, Water for injection.



It's a CE-marked medical device. Read instructions and warnings before using.









DERMOCOSMETICA

Distribuit de:

**ITALTRADE & CO SRL**

Calea București Nr. 74, Tunari, Ilfov,  
077180, București, România

**[www.italtrade.ro](http://www.italtrade.ro)**

Mobil: +40 759 059 540

Telefon: +40 213.165.070

E-mail: [office@italtrade.ro](mailto:office@italtrade.ro)

**I.C.S. DERMOCOSMETICA S.R.L.**

str. Constantin Brîncuși nr. 112,  
birou 8, mun. Chișinău, Republica  
Moldova

**[www.dermocosmetica.md](http://www.dermocosmetica.md)**

Telefon: +373 (60) 841114

+373 (68) 888775

E-mail: [office@dermocosmetica.md](mailto:office@dermocosmetica.md)